

---

## The Early Development of the Pericardium, Diaphragm, and Great Veins

C. B. Lockwood

*Phil. Trans. R. Soc. Lond. B* 1888 **179**, 365-384  
doi: 10.1098/rstb.1888.0013

---

### Email alerting service

Receive free email alerts when new articles cite this article - sign up in the box at the top right-hand corner of the article or click [here](#)

---

To subscribe to *Phil. Trans. R. Soc. Lond. B* go to: <http://rstb.royalsocietypublishing.org/subscriptions>

---

XIII. *The Early Development of the Pericardium, Diaphragm, and Great Veins.*

By C. B. LOCKWOOD, *F.R.C.S.*, *Hunterian Professor of Anatomy, Royal College of Surgeons of England.*

*Communicated by G. M. HUMPHRY, F.R.S.*

Received November 26,—Read December 15, 1887.

Revised June 15, 1888.

[PLATES 53–61.]

THE following investigation was begun three years ago with a view to inquire into the development of the pericardium, but it transpired that this question is inseparable from that of the development of the heart, great veins, and diaphragm. Since the Avian pericardium is complicated by various septa whose exact nature is not generally agreed upon,\* the embryos of Mammals, especially of Rabbits, have been used for the investigation, and Human embryos have been obtained to illustrate some of the later stages. But, as the embryo of the Rabbit is capricious in its development, it is hardly possible to say upon any particular day after impregnation what stage the embryos may have attained. As a rule, the various members of a litter differ amongst themselves, some being more advanced than others; so that, without this qualification, it would be misleading to specify, as some authors have done, the exact age of the embryo described or depicted.

The origin of the Mammalian heart has been elucidated by various observers, especially by BALFOUR,† HENSEN,‡ HIS,§ and KÖLLIKER,|| and only requires to be mentioned so far as it bears upon the present inquiry. In the Rabbit the organ begins to develop during the first half of the eighth day. And its commencement is indicated by a slight bending of the splanchnopleure into the widely separated halves of the cœlom (fig. 1, *Ht.*). This loop is thicker than the rest of the splanchnopleure,

\* HUXLEY, "On the Respiratory Organs of the Apteryx," 'Zool. Soc. Proc.,' 1882, p. 560.

† 'A Treatise on Comparative Embryology,' by FRANCIS M. BALFOUR, London, 1885, vol. 2, p. 633.

‡ "Beobachtungen über die Befruchtung und Entwicklung des Kaninchens und Meerschweinchens," v. HENSEN, 'Zeitschrift für Anatomie und Entwicklungsgeschichte,' 1876, p. 344.

§ "Mittheilungen zur Embryologie der Säugethiere und des Menschen," W. HIS, 'Archiv für Anatomie und Physiologie,' 1881, pp. 302 *et seq.*; also 'Anatomie Menschlicher Embryonen,' Leipzig, vols. 1, 2, and 3, and plates.

|| 'Entwicklungsgeschichte des Menschen und der Höheren Thiere,' Leipzig, 1879, p. 289.

owing to multiplication and elongation of its cells. At this time the portion of the cœlom into which the cardiac loops project is more capacious than the rest, but has not the same lateral extension. Its somatopleure, after running a little way outwards, turns abruptly ventralwards to join the splanchnopleure. At the foremost end of the rudimentary heart, where the bending of the somatopleure is greatest, both membranes disassociate themselves at an early period from the peripheral unleft mesoblast; but further back they retain their original connexions. The accompanying drawing was made from a section which was slightly oblique, and illustrates both of these points (fig. 1). Afterwards, as development proceeds, the whole of the cardio-cephalic region ultimately frees itself in this way from the peripheral unleft mesoblast.

The splanchnic cardiac loops grow rapidly during the eighth day, and each acquires an endothelial lining. The latter, as BALFOUR points out, is derived from the splanchnic mesoblast, and cells of a similar nature reach inwards towards the notochord, and are concerned in the formation of the dorsal aortæ. The endothelial linings form a continuous ring, although the splanchnic cardiac loops are incomplete ventralwards (fig. 2, *Ht.*). As the pharynx closes in, the separate halves of the heart gradually approximate (fig. 3, *Ht.*), and finally unite at the ventral aspect of the alimentary canal. When this is completed the heart remains for a time attached to the pharynx by the mesocardium posterius, and to the ventral wall of the cœlom by the mesocardium anterius. From the fore end of the heart the aortæ pass round the pharynx to join the dorsal aortæ, which, although distinctly formed, have not as yet coalesced. During the first half of the eighth day the aortæ are the only vessels which leave or enter the heart, but afterwards the vitelline veins develop and exercise an important influence upon the development of the pericardium. The specimens in my possession (fig. 3) do not seem to favour the view that the cardiac loops become complete tubes before their union\*; it seems as if their concavities merely come together and unite; but, of course, the endothelial linings must be excepted from this statement. Moreover, as the halves of the heart join together the continuity of the hypoblast between them is broken, and its epithelium takes no part in the formation of the organ. Hence it follows that the hypoblast which lines the pharynx ceases to unite with that which clothes the ventral aspect of the cardiac cœlom by passing through the heart or mesocardia.

The effect of these changes upon the cardiac cœlom is comparatively simple. As the splanchnopleure closes in to form the pharynx the separate halves of the cœlom come together, but are, at first, partitioned from one another by the mesocardium posterius and anterius, with the heart in their midst; and thus a ventral mesentery originates which is attached to the pharynx and supports the heart.

By the beginning of the ninth day the mesocardium anterius has disappeared, with the exception of a small remnant which persists for some days, and the halves of the

\* BALFOUR, 'Elements of Embryology,' vol. 2, p. 633.

cardiac cœlom coalesce to form a single chamber. The foremost portion of the heart, owing, presumably, to the shortness of the supracardiac splanchnopleure, has a wide attachment to the pharynx, but the mesocardium posterius forms a thin support for the venous end (figs. 15B and 16B). By this time, moreover, the vitelline veins have appeared, and run inwards from the vascular area, at right angles to the axis of the embryo, to enter the heart (fig. 4, *Vit. V.*). These vessels begin in the vascular area by means of a venous mesh-work,\* and reach the heart by way of the splanchnopleure, and, consequently, by passing across the ventral boundary of the cœlom. As their passage is at right angles to the axis of the embryo, they form a demarcation between the cardiac and pleuro-peritoneal portions of that space. This may be proved by longitudinal sections of embryos of the beginning of the ninth day, which, uncut and slightly magnified, have the appearances shown in the accompanying figure (fig. 4). The sections show that on each side of the pharynx the cœlom is continuous at the dorsal aspect of the vitelline veins (figs. 10A, 11A, *Vit. V.*; and fig. 5, *Vit. V.*); and that the part of it in front of those vessels contains the heart, although that behind is, as yet, unoccupied by either lungs or abdominal viscera.

Towards the lateral limits of the embryo, the vitelline veins lie at the foremost end of the pleuro-peritoneal space, and the mesoblast in front of them is uncleft, because, as I have pointed out, the cardiac cœlom does not extend so far outwards (figs. 7A and 8A and *Vit. V.* and *Blas.*, and 9A, *Vit. V.*). In consequence of this, the vein is situated at the junction of the somatopleure and splanchnopleure, and might, not unreasonably, have been thought to unite them. This junction is that which KÖLLIKER† has named “mesocardium laterale;” but, inasmuch as it does not, in the earliest stages, form a mesentery for the heart, this term does not seem entirely appropriate; at later stages this objection disappears, and, as the name is well known, it deserves to be retained.

In future I propose to call the passage by which the cardiac and pleuro-peritoneal portions of the cœlom communicate the “iter venosum,” because the great veins have so much to do with its formation, and subsequently with its closure. Its presence has been recognised by HIS‡ and USKOW§ both in Rabbits and Human embryos. The former author seems reluctant to look upon the pericardium as essentially a portion of the cœlom, and considers that which I have called the iter to have two parts, which he calls the “recessus parietalis” and “recessus abdominalis” respectively. These names are only applicable, however, to those portions of the cardiac and pleuro-peritoneal cœlom which, at later stages, lead towards the heart. When the lungs develop

\* “Recherches sur la formation des annexes fœtales chez les Mammifères.” E. VAN BENEDEEN and C. JULIN, ‘Archives de Biologie,’ vol. 5, 1884, p. 381.

† “Entwicklungsgeschichte,” p. 295 (figs. 214 and 217).

‡ HIS, “Mittheilungen zur Embryologie der Säugethiere,” ‘Archiv für Anatomie und Entwicklungsgeschichte,’ 1881, p. 303.

§ USKOW, “Ueber die Entwicklung des Zwerchfells, des Pericardiums und des Cœloms.” ‘Archiv f. Anat. und Physiol.,’ vol. 12, 1883, pp. 143 *et seq.*

they protrude into the recessus abdominalis, so that it has also been called by HIS the recessus pulmonalis.\* Further, it can easily be perceived that the iter venosum corresponds to the passage which in many Vertebrates, especially the Skate and Dogfish, unites the pericardium with the rest of the body cavity, and whose origin, BALFOUR says, has not been satisfactorily worked out.† It may be inferred from the foregoing that the iter venosum is bounded ventralwards by the vitelline vein, dorsalwards by the body wall, externally by the mesocardium laterale, and internally by the splanchnopleure, where that membrane is closing in behind the venous end of the heart to form the fore-gut and mesocardium posterius (figs. 16B and 20c, *It. V.*). Behind the heart and vitelline veins the splanchnopleure has not as yet infolded to form the alimentary canal, but runs outwards on either side to unite with the somatopleure (figs. 17B and 18B, *Spl.*). Longitudinal sections near the axis of the embryo and internal to the iter show the heart in its relation to the pharynx (figs. 13A and 14A), and their appearances have been rendered familiar by KÖLLIKER,‡ USKOW, and others. Taken alone, they suggest that the heart lies in a separate and distinct chamber of its own; but such an idea is shown to be erroneous, both by earlier embryos and by the other sections through the iter. The appearance seems due to the fact that in the cardiac region the halves of the cœlom have already coalesced, whilst behind they are still apart; so that, in consequence, the splanchnopleure which spreads outwards from one to the other envelops the venous end of the heart (fig. 14A), and thus seems to form a closed chamber for it.

Soon after the heart has become an unpaired organ the ventral wall of the cardiac chamber alters so much that the share the splanchnopleure has in its formation is less obvious. It seems reasonable to infer that, inasmuch as its ventral boundary wall is covered with hypoblast, therefore it is of splanchnic origin, and this is borne out by the younger embryos (figs. 1 to 3, *Hy.*). In longitudinal sections, as VAN BENEDEEN and JULIN also show, the hypoblast extends forwards over the ventral wall of the cardiac cœlom to form, with the epiblast, the pro-amnion (fig. 5, *P. am.*).

Authorities are agreed that the mesocardium laterale plays an important part in the development of the pericardium, but some of its features, I think, require further elucidation. Its formation seems to be exceedingly constant in the vertebrate series, and it is recognised to be a junction of splanchnopleure to somatopleure, which serves for the transmission of the somatic venous system into the splanchnic. The former would, in the earlier stages of development, comprise the umbilical veins, the cardinal veins, and the Cuvierian ducts; the latter the vitelline veins and heart.

The question arises whether, as KÖLLIKER§ and BALFOUR|| seem to think, the

\* 'Anatomie Menschlicher Embryonen,' pt. 3, p. 146.

† 'Comp. Embryol.' vol. 2, p. 628.

‡ *Loc. cit.*, pp. 407 *et. seq.*

§ *Loc. cit.*, p. 295.

|| *Loc. cit.*, vol. 2, p. 627.

mesocardium laterale is an actual adhesion of the somatopleure to the splanchnopleure, or whether it is a place at which the mesoblast has never separated into those layers. Studied in some transverse sections, and, perhaps, at rather later stages, it seems to possess the characters of an adhesion, and it may in some types, Birds for instance, be of that nature; but in the Rabbit, as we have already seen, it is the place at which the cleft mesoblast gives place to that which is uncleft (*M.L.*, figs. 7A and 8A and 9A). The exact position of the mesocardium laterale in a series of sections is marked by the passage of the somatic veins into the splanchnic, and in the embryo which has been figured a vein, which will presently be identified as the umbilical, runs forwards in the somatopleure to empty into the vitelline (fig. 8A, *U.V.*). As I have just remarked, the mesocardium laterale has the appearances of an adhesion in transverse sections (figs. 16B and 21C *M.L.*); but, nevertheless, even transverse sections bear out the previous statements.

Various opinions prevail as to the identity of the vein which passes through the mesocardium laterale. KÖLLIKER\* and USKOW† call it the jugular,‡ whilst BALFOUR speaks of it as being the Cuvierian duct. Neither of these alternatives holds good in the Rabbit's embryo, because the vein which their mesocardium laterale transmits runs from the tail end forwards in the side body wall (fig. 8A, *U.V.*, also figs. 16B, 17B, and 18B, *U.V.*), and, therefore, corresponds neither to the jugular vein nor to the Cuvierian duct. At first (early part of ninth day in Rabbit) the anterior cardinal or jugular veins are merely represented by isolated venous spaces by the side of the brain (fig. 15B, *J.V.*), and the posterior cardinals by similar spaces near the Wolffian ducts and tubules (fig. 18B, *P.C.V.*). However, in addition to these, at the level of the mesocardium laterale the body wall contains on each side a spacious vessel, the umbilical, or parietal, vein. These paired vessels run tailwards in the body wall (fig. 18B, *U.V.*), until they reach the level of the posterior neurenteric canal, where they turn dorsalwards in a portion of the body wall which is continuous with the tail fold of the amnion (fig. 19B, *U.V.*), and in which they communicate with one another, and, as will be described, obtain a connexion with the endometrium.

The umbilical veins develop after the mesocardium laterale, and sooner upon one side of the embryo than upon the other. At the beginning of the ninth day the mesocardium laterale exists on both sides, although only one umbilical vein may have developed, and that partially, as happens to have been the case in one of the embryos depicted (fig. 8A, *U.V.*). Moreover, those vessels do not both acquire a passage towards the heart at the same moment, for sometimes, although each is present, only one may open into the vitelline vein, whilst the other is still separated from it by a thin partition (compare fig. 16B with fig. 17B, *U.V.*). At first the umbilical veins only

\* 'Entwicklungsgeschichte,' p. 296, fig. 215.

† USKOW, *loc. cit.*, p. 167.

‡ In these pages the term "jugular vein" is considered as being synonymous with "anterior cardinal vein."

reach as far forwards as the mesocardium laterale, but later they extend a little further towards the head (seven sections in Series B.), and, as, will be seen later, their foremost part receives the anterior cardinal or jugular veins when those vessels are more fully developed. The portions of the vitelline veins into which the umbilical veins empty themselves cross the ventral boundary of the iter venosum, and, after uniting with each other behind the heart, open together into the venous end of that organ (figs. 14A and 21c, *Vit. V.* and *S.R.*). During the early hours of the ninth day the capacity of these portions of the vitelline veins increases rapidly, and at the same time their connexions by means of the mesocardium laterale and posterius with the body wall and pharynx become more substantial (fig. 20c). Being held by these attachments, the vitelline veins prevent the expansion of the part of the cœlom at their dorsal aspect, and it remains in consequence a narrow passage, the iter venosum. The expanded portion of the vitelline veins may be identified as an early stage of the chamber which HIS\* has named the sinus reuniens, and which, after its formation, becomes the ventral boundary of the iter venosum. After these events the iter venosum is by far the narrowest part of the cœlom, and forms a decided constriction between its cardiac and pleuro-peritoneal portions; and, in addition, the septum transversum, or primitive diaphragm, has originated in the following manner:—At the beginning of the ninth day the splanchnopleure, after being attached to the ventral wall of the vitelline vein, is prolonged forwards over the heart without exhibiting any particular bend ventralwards (figs. 9A, 10A, and 11A, *Spl.*). But in embryos of nine days and four hours that membrane, and the hypoblast which covers it, makes a decided bulge where it clothes the ventral aspect of the heart, and is sharply retroflected behind that organ (fig. 5, *Spl.*). This is caused by several circumstances. The expansion and growth of the heart is one of the chief, causing the splanchnopleure, or as this part of it is sometimes called, the cardiopleure, to bulge at its ventral aspect, but the effect of this is limited, and cannot alter the position of that part of the membrane which is continuous with the vitelline veins, or, as they may now be called, the sinus reuniens. This, owing to the attachments of the vitelline veins to the dorsal body wall and pharynx, by means of the mesocardium posterius and laterale, cannot undergo displacement, and, obviously, its fixation is exactly opposite the iter venosum (fig. 5, *It. V.*). The formation of the cranial flexure has also an influence upon the early development of the septum transversum, for it carries no inconsiderable part of the heart and splanchnopleure tailwards beneath the vitelline veins. Another feature of this splanchnic retroflexion is that it stretches across the axis of the embryo from one mesocardium laterale to the other; although, at this stage of the development of the cardio-cephalic region, its mesoblast still passes beyond those limits to become continuous with the peripheral uncleft mesoblast (fig. 22c, *P.M.*). Thus a transverse septum is formed from the splanchnopleure, the anterior surface of which is concave, and supports the heart and gives attachment to

\* HIS, 'Anatomie Menschlicher Embryonen,' part 3, p. 144.

the remains of the mesocardium anterius and posterius; whilst its hinder surface, prior to the development of the liver or closure of the alimentary canal, protrudes into the capacious mouth of the vitelline duct (fig. 5, *S.T.*). Most authors have described the septum transversum after the liver has developed, and, therefore, the splanchnic retroflexion which has just been described only resembles the "septum transversum" of HIS,\* or the "cloison transversale" of CADIAT,† or the "massa transversa" of USKOW,‡ in its relations to the heart and sinus reuniens. However, its identity and more permanent characters will be evident after the liver has developed.

In the Rabbit, and probably in other Mammals, the liver develops upon the hinder surface of the septum transversum. A thickening of the hypoblast and mesoblast on either side of the alimentary canal, and opposite the iter venosum, and close to the ventral wall of the vitelline vein, indicates its commencement (*H. Hy.*, fig. 5, and *L.*, fig. 6). The median part of the septum does not at first participate, but subsequently its cells grow larger, like the rest, and multiply and dispose themselves irregularly in the thickened mesoblast (fig. 22c) and, at the same time, vascular channels appear which acquire openings into the lumens of the vitelline veins. Thus, at its commencement the liver seems to be, in a degree, a bilateral development. After their formation, the liver and septum transversum increase rather rapidly, and the mesocardium laterale becomes thicker (*L.* and *M. L.*, fig. 6). The anterior cardinal veins also develop more completely at this stage (*A. C. V.*, fig. 6), and run along the body wall, past the iter venosum, to empty into the umbilical veins, just before the latter pass through the mesocardium laterale on their way into the sinus reuniens, whose capacity has also increased. The venous spaces which represent the posterior cardinal veins have not, as yet, acquired a passage into the heart. During these events the liver continues to grow upon the septum transversum (*L.*, fig. 24d, also *L.*, fig. 36), until it becomes an organ of some size situated behind the heart and upon the ventral wall of the vitelline veins and sinus reuniens (*L.*, fig. 32E). A number of solid villous processes are associated with its growth, and by their union help to form its substance; others may be observed which, like pseudopodia, project from the ventral wall of the pericardium (fig. 36, *Vil. P.*); these, however, disappear without, as far as can be seen, performing any function. By the eleventh day the septum transversum has become the ventral part of the diaphragm (fig. 42F and 43F, *S. T.*), and a little later, both in Rabbits and Human embryos, its appearances are quite familiar (*V. D.*, fig. 53, also fig. 54H). Soon after the commencement of the liver the somatopleure and splanchnopleure infold in the usual manner, and as the former wraps round the liver it unites on either side with its substance (figs. 24d and 44F). As the splanchnopleure infolds it forms a

\* 'Anatomie Menschlicher Embryonen,' vol. 1, p. 125.

† "Du Développement de la Portion Céphalo-Thoracique de l'Embryon, &c.," 'Journal de l'Anatomie et de la Physiologie,' vol. 14, 1878, p. 620.

‡ *Loc. cit.*, p. 171.



dorsal mesentery, which supports the gut (fig. 23D, *Mes. D.*), and a ventral mesentery, which unites the foremost part of its ventral edge to the liver (fig. 24D, *Mes. D.*). A portion of the latter persists as the gastro-hepatic ligament, or lesser omentum; the remainder disappears, although until the twelfth day it is continuous with the blastoderm, and is the route by which the vitelline veins enter. The last-named vessels, after the splanchnopleure has infolded, run forwards by the side of the alimentary canal, at the dorsal surface of the liver and septum transversum (*Vit. V.*, fig. 24D and 25D), as far as the mesocardium laterale, where they receive the umbilical veins and become the sinus reuniens (fig. 26D). The cardiac ends of the umbilical veins are at first unaffected by the infolding of the body wall, but whilst that event is progressing the part of the body wall in which they commence becomes converted into the foetal part of the placenta.

We have already seen that at the beginning of the ninth day the umbilical veins commence in a portion of the body wall which is continuous with the tail fold of the amnion (fig. 19B); by the middle of the same day the body wall in this region has grown thicker and has still retained its vascularity (figs. 26D, 27D, and 28D); and by the end of the ninth day these changes have advanced further, and there are indications that the portion of the body wall in which they are in progress is being constricted from the rest to become the foetal placenta (fig. 31, *Plac.*). This placental region of the embryo has never wholly separated from the endometrium, although the position of the embryo with regard to the uterine wall has completely changed. During the eighth day the dorsum of the embryo, covered with epiblast, lies in contact with the uterine wall (figs. 1 and 4). The position is the same at the beginning of the ninth day, except that the embryo has parted a short distance from the uterine wall, from which it is partially separated by the folds of the amnion (fig. 14A, also figs. 15B and 16B). Later, the cranial flexure carries the cardio-cephalic region and pro-amnion ventralwards into the interior of the blastodermic vesicle (figs. 5 and 6), and after a while that bend increases so much that the head and tail ends nearly meet (fig. 32E). Whilst these movements are proceeding the embryo turns over upon its right side, carrying the amnion with it (fig. 24D and fig. 31), and its right side then lies upon the uterine wall; and in the placental region this rotation is so complete that its venter is completely turned towards the uterus (figs. 27D and 28D, also fig. 30). Also, in that region, the body wall seems never to entirely dissociate itself from the endometrium, or from the rest of the blastoderm.

Thus, the commencements of the umbilical veins acquire their connexion with the uterine wall without the aid of an allantois. I do not propose at present to consider the development of that organ; but I am unable to confirm the late Professor BALFOUR's statement that the allantois of the Rabbit is formed the same way as in Birds\*; nor do KÖLLIKER's observations seem to convey a clearer impression of the

\* 'Comparative Embryology,' vol. 2, p. 281.

actual processes of development. Most authors adopt the views of VON BISCHOFF,\* who speaks of and depicts the allantois as a vesicular protrusion which, he says, grows towards and adheres to the uterine wall.† The placental stalk of the Rabbit's embryo has at the twelfth day the appearances which VON BISCHOFF describes and depicts, but it bends to the right, not because of its own movements, but because of the rotation of the embryo, nor does it protrude or grow towards the uterine wall. It is true that at the middle of the ninth day the lumen of the hind gut extends into the foetal placenta (compare figs. 29D, 28D, and 27D, *All.*), but other specimens suggest that this extension, which corresponds to the allantois of other types, is formed by inclusion and not by protrusion (fig. 30, *All.*), and this circumstance throws light upon the pathology of ectopia vesicæ. Moreover, the splanchnopleure itself seems to take no part in the development of the placenta, for the placental and caudal portions of the Rabbit's embryo develop in the space which there is between that membrane and the uterine wall, the latter being covered with the subzonal membrane (*Spl.*, fig. 14A, also figs. 30 and 31).

The further progress of the heart and venous system and the appearance of an air-breathing apparatus tend to the development of the pericardium and permanent diaphragm. One of the most important events is the formation of the ductus Cuvieri, and their subsequent conversion into the superior venæ cavæ. The history of the somatic venous system has been followed until it comprises an umbilical and a jugular vein on either side, which coalesce in the body wall opposite the mesocardium laterale, through which they pass to empty into the sinus reuniens. As the Wolffian duct and tubules grow (second half of the ninth day) the posterior cardinals undergo further development, and run forwards and empty into the jugulars, just before the latter cross the iter venosum (figs. 33E and 34E, *P. C. V.*). This converts a portion of each of the jugular veins into the ductus Cuvieri, which still pursue the original course of the jugulars through the body wall, and past the iter (figs. 33E and 36, *C. D.*, also fig. 6, *A. C. V.*). Afterwards (second half of tenth day) the growth of the head and of the primitive kidneys and vertebræ is rapid, and in consequence the ductus Cuvieri, which return the blood from both regions, expand and encroach upon the lumen of the iter venosum (figs. 37F and 38F, *R.* and *L. C. D.* and *It. V.*). Next, the fore limbs develop, and send their venous blood by the subclavian veins into the ductus Cuvieri, and convert them into the superior venæ cavæ (fig. 47G, *S. V.* and *V. C. S.*). This conversion is accompanied by a further encroachment of the veins upon the iter venosum, which persists for a time as a narrow chink between the vein and the alimentary canal, but this finally disappears (fig. 47G, *It. V.*). In the Rabbit the passage is largest at the end of the ninth and during the tenth day, and is closed by the commencement of the thirteenth. I have never seen its lumen divided in more than

\* 'Entwicklungsgeschichte,' p. 286.

† 'Entwicklungsgeschichte des Kaninchen-Eies,' pp. 134 and 137, pl. 15, figs. 62 and 63.

four or five of a series of longitudinal sections. Its closure is assisted by the growth of the mesoblast round the trachea and œsophagus, and seems to be effected in the same manner in the Human embryo as in the Rabbit, as may be seen by comparing the accompanying drawing of a transverse section of an early Human embryo with those of the Rabbit (fig. 46, *It. V.*). In rare instances the iter venosum may persist, and I have seen in a Human foetus an aperture at the inner side of the vena cava superior which opened from the pericardial into the pleural sac; this patency was associated with a tri-coelian heart and other abnormalities.

The closure of the passage which I have ventured to call the "iter venosum" is a matter of dispute. HIS, writing in 1881,\* attributes the closure in Rabbits and Man mainly to the approximation of the Cuvierian ducts. I myself had arrived at a similar conclusion before having seen HIS's paper. USKOW† mentions three main factors in the occlusion. 1. The general alteration in the position of the foremost part of the mesocardium laterale. 2. A thickening of the "massa longitudinalis" (a name which the author gives to the tissues along the side of the trachea and œsophagus). 3. A cell increase in the "massa transversa" (*i.e.*, the dorsal part of the diaphragmatic mesoblast). This author also mentions the ducts of CUVIER in this connexion, but does not, in my opinion, attach sufficient importance to the part they play. The names "massa transversa" and "massa longitudinalis," which USKOW uses, seem to me superfluous.

Whilst the iter venosum is being occluded the lungs protrude from the œsophagus into the recessus abdominalis, and soon afterwards a septum, the dorsal pericardium,‡ originates betwixt them and the heart. The development of the dorsal pericardium is preceded by changes in the cardiac endings of the great veins, due to a gradual expansion of the sinus reuniens, and therefore these changes may be mentioned before the septum. The sinus, as we have seen, is formed from the cardiac ends of the vitelline veins, and retains for a time the features of those vessels, and is situated at the dorsal edge of the primitive splanchnic retroflexion, or septum transversum. By the time the jugular veins have appeared the sinus reuniens has expanded and become more capacious, but it does not at first receive those vessels, for, as we have seen, they open into the ends of the umbilical veins (fig. 6, *A. C. V.*). As the expansion of the sinus reuniens proceeds it involves the mouths of the umbilical veins, and they are gradually merged into, and become part of, the sinus (fig. 36, *S. R.* and *L. U. V.*, also figs. 33E and 38F and 39F, *R. U. V.* and *S. R.*); and at last it progresses so far that the jugular veins (or ductus Cuvieri) acquire separate openings of their own (figs. 37F, 38F, *S. R.* and *R.*, and *L. C. D.*). Thus, by the time the lungs and pericardium have begun (eleventh day), the sinus reuniens receives on either side three great veins,

\* "Mittheilungen zur Emb. der Säugethiere, &c.," 'Arch. für Anat. und Phys.,' 1881, p. 318.

† *Ibid.*, p. 174.

‡ Called by some authors, SCHMIDT, HIS, and USKOW, *membrana pleuro-pericardiaca*.

namely, the vitelline, the umbilical, and ductus Cuvieri. At this stage it is situated at the dorsal part of the septum transversum, and not beneath it, as it is said to be in the Human embryo; moreover, it opens into the auricle by a wide mouth, and not by a narrow porta vestibuli;\* also, by the time these changes have taken place in the terminations of the umbilical veins, each of those vessels has acquired communications with the hepatic venous spaces (fig. 41F, *R. U. V.* and *L. U. V.*), and, on the left side, this new communication ultimately becomes the ductus venosus Arantii.

The separation of the Cuvierian ducts from the umbilical veins is accompanied by an elongation of the mesocardium laterale, which becomes a short and thick septum, the dorsal pericardium, between the recessus *pulmonalis* and the pericardial sac. This septum begins in front at the ductus Cuvieri (figs. 37F, 39F, and 40F, *D. P.*), and is continuous behind with the dorsal part of the septum transversum; which, after a while, also assists in the formation of the pericardium. At its junction with the septum transversum the dorsal pericardium widens out to transmit the umbilical veins (figs. 39F, 41F, and 42F, *R. U. V.* and *L. U. V.*). In subsequent stages, as the lungs grow and as the thorax develops, the dorsal pericardium increases in *width* (figs. 49G and 50G, *D. P.*), and as the lungs expand it gradually becomes an extensive and tenuous membrane, the permanent pericardium (fig. 57I, also fig. 62, *D. P.*). The *length* of the dorsal pericardium is at first insignificant, for it only reaches from the Cuvierian ducts as far as the septum transversum, or ventral diaphragm. Before the lungs develop the ducts and ventral diaphragm are close to one another (fig. 54H, *L. C. D.* and *V. D.*); but as those organs grow the thorax elongates and the ducts and diaphragm are carried apart, so that the pericardium becomes longer † (figs. 53 and 54H, *D. P.*); and this applies both to the Rabbit and to the Human embryo, and without doubt the mesoblast of the dorsal part of the ventral diaphragm, and in the neighbourhood of the sinus reuniens, assists by its elongation in its formation. Thus, the development of the pericardium is mainly dependent upon the expansion and elongation of the thoracic region which accompanies the development of the lungs. But the formation of an air breathing apparatus entails changes in the heart and vascular septum which have also an influence. One of the events is the shrinking of the sinus reuniens and its ultimate conversion into the saccus reuniens (His). ‡ This process is preceded by the obliteration of various portions of the umbilical and vitelline veins, and before its completion the pulmonary veins and left auricle have originated, and, moreover, the heart itself has travelled backwards away from the head. Both of the umbilical veins lose their cardiac openings as the thoracic portion of the embryo elongates; and as the liver develops the right vein disappears

\* His, 'Anat. Mensch. Embryonen,' pt. 3, pp. 145 and 202.

† His, *loc. cit.*, p. 146, attributes the formation of the dorsal pericardium to the separation of the Cuvierian ducts from the body wall.

‡ *Loc. cit.*, pt. 3, p. 145.

entirely, although traces of its trunk can be detected in the body wall for some time after it has ceased to perform any function. As the cardiac opening of the left umbilical vein closes, the communication which its trunk has previously acquired with the hepatic venous spaces (fig. 41F, *R. U. V.* and *L. U. V.*) gradually becomes more free, and at last (twelve and a half days), by dilatation of the spaces, a channel is formed in the liver substance, and, conveys the blood of the left umbilical vein across into the end of the right vitelline and so onwards into the sinus reuniens (figs. 50G, 51G, and 52G). For some time after the obliteration of the cardiac end of the left umbilical vein its lumen persists in the body wall, in front of the commencement of the ductus venosus Arantii (fig. 52G, *L. U. V.* and *D. V. A.*). After the closure of the cardiac ends of the umbilical veins the junction of the dorsal pericardium and septum transversum, through which they previously passed, remains as a solid septum betwixt the lungs and the heart.

After the development of the stomach and alimentary canal the course of the vitelline veins consists of three parts, a mesenteric, a hepatic, and a septal. The first and second of these hardly require an explanation, the third is a portion of each vitelline vein which lies between the liver and the sinus reuniens, and which projects dorsalwards from that chamber and the septum transversum into the recessus pulmonalis (figs. 38F, 39F, *S.R. Vit. V.*). Inasmuch as both the vitelline veins do not share the same fate, they require to be considered separately. When the sinus reuniens has undergone expansion (11th day) the hepatic part of the left vitelline vein begins to be occluded with liver substance (fig. 42F, *L., Vit. V.*), and after a while the dorsal lobe of the liver no longer betrays any traces of its presence (fig. 51G, *D.L.*). Simultaneously the vein ceases to open into the sinus reuniens, although vestiges of it may be still found in the dorsal pericardium, close to where that structure is continuous with the septum transversum, or, as it may now be called, the ventral diaphragm (fig. 50G, *L., Vit. V.*). The mesenteric part of the left vitelline vein also disappears, except a short length near the vitelline duct, which makes its way into the right vitelline vein; this seems to be the only communication between the two vessels, and, although others have been described in Human embryos, the material in my possession leads me to think that some of them cannot be constant.\*

The early obliteration of the septal and hepatic portions of the left vitelline vein has, without doubt, an adverse effect upon the development of the left lobe of the liver and also upon that of the left side of the pericardium and ventral diaphragm. Those structures, more particularly the left lobe of the liver and ventral diaphragm, develop less than the right, and in consequence the left recessus pulmonalis is the most capacious. Under these circumstances, it may be assumed that it would require a greater developmental effort to partition the left recessus pulmonalis from the peritoneum than the right, and, therefore, that failures would be commonest on

\* HIS, *loc. cit.*, p. 202.

that side. This is actually the case, for we find that, although congenital absence of the hinder part of the diaphragm is common on either side, yet it is commonest on the left in the proportion of five to one.\*

As far as we have followed the history of the right vitelline vein, it has passed through the following stages:—At first it carried blood back from the vascular area; then this was augmented with that from the umbilical veins and liver, and afterwards with the whole of the blood of the left umbilical vein through the ductus venosus Arantii. Before the ductus venosus develops the septal part of the right vitelline vein lies close to the body wall upon the dorsum of the sinus reuniens and septum transversum (figs. 38F and 39F, *S.R.* and *S.R. Vit. V.*). But after the obliteration of the cardiac ends of the umbilical veins, the shrinking of the sinus reuniens, and the formation of the dorsal pericardium, it is separated from the body wall, and instead of projecting into the recessus pulmonalis lies more in the substance of the dorsal pericardium (fig. 50G, *R. Vit. V.*). It is still close to the sinus reuniens, but that chamber has become smaller and has to a large extent disassociated itself from the septum transversum, and lies between it and the heart (fig. 55H, *S.R.*, also fig. 57I, *S.R.*). As the thorax and pericardium develop the likeness of the septal portion of the right vitelline vein to the thoracic part of the vena cava inferior becomes unmistakable (figs. 60I and 61I, *V.C.I.*).† And, in addition, whilst the change is being effected, the hinder part of the vena cava inferior develops and sends its blood to the heart by the vessel in question. The vena cava inferior appears both in Rabbits and in Human embryos either before or simultaneously with the permanent kidneys (beginning of 13th day in the Rabbit). It commences a little in front of those organs by two blind symmetrical rootlets (the renal veins), situated at the base of the mesentery, and in front of the aorta. After communicating with both posterior cardinal veins, especially with the right, it runs forwards by the side of the aorta, and enters the liver and runs through the substance of that organ to empty into the right vitelline vein in front of its junction with the ductus venosus Arantii. The vena cava enters the liver through a junction (the caval junction) which that organ previously acquires with the tissues at the base of the mesentery (fig. 52G, *C.J.*). The right vitelline vein also receives numerous branches from the stomach, pancreas, spleen, and intestines as those organs develop, and becomes the portal vein (fig. 54H, *R. Vit. V.*). It retains for a time its direct communication with the ductus venosus, but finally its lumen becomes occluded with liver substance, and it ends in small channels, which are the beginning of the interlobular veins.‡

\* LICHTENSTERN, 'Cyclopædia of the Practice of Medicine,' Ziemssen, vol. 7, p. 554.

† HIS calls this part of the right vitelline vein the ductus venosus Arantii, *loc. cit.*, p. 102, fig. 100.

‡ So many different accounts are given of the development of the venous system that it would be a very lengthy task to collate them. KÖLLIKER, in his 'Entwicklungsgeschichte,' p. 915, gives a clear account of them. That which I have given accords most nearly with HIS's description (*loc. cit.*, p. 207), with the exception of the thoracic portion of the vena cava inferior and of the various communications between the vitelline veins.

In the higher Mammals the diaphragm usually consists of three parts—namely, of a central part, in relation with the pericardium and heart; of lateral parts, which are muscular; and of crura. So far I have only traced the origin of the central part, that which is interposed between the heart and liver. This is at first a thin layer of mesoblast, whose cells are arranged transversely (figs. 42F and 43F, also figs. 53 and 54H, *S. T.* or *V. D.*). In many animals, *e.g.*, the Dog, Rabbit, and Man, it splits towards the end of intra-uterine life into two distinct layers—a superior, which helps to form the pericardium; and an inferior, which usually becomes tendinous, and is the tendinous centre of Human anatomists. In Man the fibrous pericardium and tendinous centre reunite after the third year, but they remain permanently apart in many Mammals, the azygos lobe being interposed between them. During the time that the Human pericardium is separable from the diaphragm it invests the thoracic part of the vena cava inferior with both its fibrous and serous layers, and these investments never entirely disappear. Further, although the liver also disassociates itself very widely from the central part of the diaphragm (figs. 63J and 64J), yet it always retains part of its original connexions by means of the lateral, coronary, and falciform ligaments. These are so arranged in most of the higher Mammals that they bisect each leaflet of the tendinous centre, and do not as a rule pass beyond their limits. The coronary ligament is complicated by the caval junction and by the development of the remaining portion of the diaphragm, the dorsal diaphragm, which will be described presently.

The sides of the diaphragm begin to develop at the same time as the lungs, and increase as the thoracic region expands. They begin as a constriction between the liver and the body wall (fig. 43F, *L.D.*), and this constricted part gradually becomes longer (figs. 51G and 60I, *L.D.*), and is finally converted, in a greater or less degree, into muscular tissue.

When the iter venosum of the Rabbit or of the Human embryo is just on the point of closure, a mesoblastic process, the dorsal diaphragm (Uskow), grows from the body wall across the recessus pulmonalis, and ultimately partitions it from the hinder part of the pleuro-peritoneal cavity and thus completes the diaphragm. The ingrowth is the same on either side, and originates far forwards, close to the Cuvierian ducts. When it is first discernible the lungs are simple diverticula from the sides of the œsophagus (figs. 49G and 55H, *Lng.*). During its early stages the dorsal diaphragm has hardly any of the characters it ultimately attains, and, therefore, it is desirable to consider it at a stage at which its identity is not doubtful, and, yet, at which it has not lost its earlier peculiarities.

The accompanying figure was made from a coronal section through a Rabbit's embryo of the early part of the fourteenth day (fig. 35, *D.D.*). It would have been better, perhaps, had the specimen been a little less advanced; but, nevertheless, it suffices to exemplify the point I wish to make clear, namely, that the lateral attachments of the dorsal diaphragm to the side body wall are nearer the head than its median connexions. At this period, the fourteenth day, the various organs are well grown,

and it is easy to recognise the dorsal diaphragm between the lungs and liver. It is a V-shaped structure, arranged so that the apex of the V blends behind with the dorsal mesentery, whilst its arms spread forwards and outwards to unite with the body wall. It is easy to infer, and presently it will be seen, what such a diaphragm would look like in transverse sections, but it is clear that, the series being begun in front, the attachment to the body wall would come into view first, and afterwards the more median portions. The dorsal diaphragm is at first (twelve and a half days in the Rabbit) of small extent, and it may only be found in seven sections of a series. Judging from both longitudinal and transverse sections, it is a partial crescent-shaped septum which grows from the body wall just behind the Cuvierian ducts (fig. 55H, *D.D.*, also fig. 48G), but is incomplete posteriorly, where its free crescentic margin projects into the pleuro-peritoneal cavity. Its dorsal attachment is just in front of the foremost end of the uro-genital ridge; ventralwards it blends with the dorsal pericardium (figs. 49G and 50G, *D.D.*), and grows tailwards along it, until, at last, it fuses with the dorsal lobe of the liver and, on the right side, with the wall of the vitelline vein, or, as it may be called, the vena cava inferior (fig. 50G, *D.D.* and *R.Vit.V.*). On the left side the vitelline vein has almost disappeared, but its remains may sometimes be seen in the pericardium, opposite the attachment of the dorsal diaphragm (fig. 50G, *L.Vit.V.*). As sections approach the hinder part of the dorsal diaphragm the whole of its extent is not divided, but only its dorsal and ventral ends. It seems unnecessary, as USKOW has done, to give names to these parts, for they have, in my opinion, no special significance: their presence is explicable if it is true that the shape of the hinder edge of the dorsal diaphragm is crescentic. In addition to the foregoing the dorsal diaphragm has two surfaces, of which one, the pleural, faces and is almost in contact with the lungs, which, before its completion, project beyond it into the hinder part of the pleuro-peritoneal sac; and another surface, the peritoneal, which is separated from the side body wall by a portion of the peritoneal cavity.

It seems hard to tell why the dorsal diaphragm should originate so far forwards. Before the vitelline veins and ductus Cuvieri separate there is, however, a process of mesoblast in the angle between them which would tend to become larger as the veins went apart (fig. 45, *D.D.*). This process is in the position of the dorsal diaphragm, and may not improbably form its starting point.

The dorsal diaphragm is incomplete and close to the foremost end of the pleuro-peritoneal sac when the cartilaginous vertebral column and ribs develop. At that time (beginning of thirteenth day in the Rabbit) the lungs, although larger, are still mere diverticula; but the pulmonary veins have originated as channels in the mesoblast which is common to them and to the œsophagus, and empty themselves into the left auricle (fig. 57I and fig. 62, *P.V.*). The dorsal diaphragm has also travelled tailwards away from the superior venæ cavæ, and is, in front, united solely to the body wall (fig. 56, *D.D.R.* and *D.D.L.*). As it runs inwards towards the mesentery it



unites with both the uro-genital ridge and with the pericardium (figs. 59I and 60I), and, finally, with a triangular mass of mesoblast which covers the dorsal lobe of the liver (figs. 59I and 60I). As yet its hinder edge is crescentic, and the lungs project beyond it into the peritoneum; but this protrusion gradually becomes less apparent (fig. 64J, *Lng.* and *D.D.*). A gradual separation of the dorsal diaphragm and mesonephros from the superior venæ cavæ accompanies the growth of the thorax. By the time the dorsal diaphragm is on the point of uniting with the mesentery it has both grown and been carried tailwards so far that its median part unites with the mesoblast which covers the dorsum of the liver some distance beyond its junction with the pericardium (fig. 63J, *D.D.*). And, in consequence, the hepatic mesoblast takes a share, as CADIAT claims, in forming the diaphragm.\*

The final closure of the aperture between the dorsal diaphragm and the mesentery has no particular feature. Before it is accomplished muscular fibres are abundant in the position of the crura and wherever the diaphragm springs from the body wall. All of these originate *in situ*, and those of the crura begin the earliest ( $12\frac{1}{2}$  days) in the base of the mesentery (fig. 54H, *Cr. D.*). After a while (14th day) they become quite distinct, and consist of bands of muscular fibres situated in front of the cartilaginous bodies of the vertebræ and at the base of the mesentery. These fibres run ventralwards round the sides of the œsophagus to spread out in the dorsal part of the ventral diaphragm, and some of them almost surround the vena cava inferior.

After the diaphragm has become a complete septum the history of its development would mainly relate to the gradual growth of the structures whose origin has been described and their gradual approximation to their permanent condition. These processes are unaccompanied by any remarkable circumstances. The main factor associated with them is the expansion of the lungs, which, in the higher types, spread ventralwards round the sides of the pericardium (fig. 62) and forwards between the superior venæ cavæ and the body wall; but, as none of these ever affect the principles of the processes which I have endeavoured to explain, I do not propose, at present, to pursue them further. However, the recess, apical recess, between the Cuvierian ducts, or superior venæ cavæ, and the body wall seems to commence at an early stage of development (figs. 37F and 39F, *R.*).

Finally, I may add that the following conclusions have been arrived at:—

1. The heart develops from splanchnopleure into the foremost end of the cœlom, which afterwards becomes the pericardial sac.
2. The cardiac portion of the cœlom is cut off by (*a*) the vitelline veins; (*b*) the Cuvierian ducts.
3. The mesocardium laterale is a point at which the mesoblast is uncleft, and at which on each side the somatic umbilical vein is transmitted into the splanchnic vitelline vein. Afterwards the mesocardium laterale transmits the Cuvierian ducts.

\* “Du Développement de la Portion Céphalo-thoracique de l'Embryon, &c.,” ‘Journal de l'Anatomie et de la Physiol.’ vol. 14, 1878, p. 620

4. The umbilical veins commence in a portion of body wall which, after the rotation of the embryo, becomes the foetal placenta. (This applies to Rabbits, and probably to Human embryos.)

5. The precedence of the great veins is as follows:—1, vitelline; 2, umbilical; 3, anterior cardinal; 4, posterior cardinal, converting a portion of anterior cardinals into the Cuvierian ducts. The whole of the right umbilical, the cardiac end of the left umbilical, and the left vitelline vein disappear, and the right vitelline becomes the portal and cardiac end of vena cava inferior. (This only applies to the early changes, and, perhaps, a small length of the commencement of the left vitelline vein may also persist.)

6. The dorsal pericardium originates from the mesocardium laterale and dorsal part of the septum transversum, the rest of the latter becoming the ventral diaphragm, *i.e.*, that between the liver and the heart.

7. The dorsal diaphragm is an ingrowth from the body wall into the recessus pulmonalis.

## ABBREVIATIONS.

<i>A. B.</i>	Aortic bulb.	<i>C. J.</i>	Caval junction.
<i>D. A.</i>	Dorsal aorta.	<i>C. S.</i>	Cardiac end of stomach.
<i>Ao.</i>	Aorta.	<i>Cr. D.</i>	Crus of diaphragm.
<i>All.</i>	Allantois.	<i>D. A.</i>	Dorsal aorta.
<i>All. V.</i>	Allantoic vein.	<i>D. D. R. and L.</i>	Dorsal diaphragm—right and left.
<i>All. Art.</i>	Allantoic artery.	<i>D. P.</i>	Dorsal pericardium.
<i>Al. C.</i>	Alimentary canal.	<i>D. L.</i>	Dorsal lobe of liver.
<i>Am.</i>	Amnion.	<i>D. S. T.</i>	Diaphragmatic portion of septum transversum.
<i>Aud. Ep.</i>	Auditory epithelium.	<i>D. V. A.</i>	Ductus venosus Arantii.
<i>Au.</i>	Auricle. R. right; L. left.	<i>End. Ht.</i>	Endothelial lining of the heart.
<i>Az. V.</i>	Azygos vein.	<i>Ep.</i>	Epiblast.
<i>Blas.</i>	Blastoderm.	<i>F. B.</i>	Fore-brain.
<i>B. A.</i>	Aortic bulb.	<i>F. L.</i>	Fore-limb.
<i>Br. A.</i>	Branchial arch.	<i>G.</i>	Gut.
<i>Br. C.</i>	Branchial cleft.	<i>H. L.</i>	Hind-limb.
<i>B. W.</i>	Body wall.	<i>Hd.</i>	Head.
<i>Blas.</i>	Blastoderm; <i>P. B.</i> , peripheral blastoderm.	<i>H. G.</i>	Hind gut.
<i>C.</i>	Cœlom.	<i>Ht.</i>	Heart.
<i>C. C.</i>	Cardiac cœlom.	<i>Hy. A.</i>	Hypogastric artery.
<i>C. V. Ant. and P.</i>	Cardinal veins—anterior and posterior.	<i>Hy.</i>	Hypoblast.
<i>C. D.</i>	Cuvierian ducts.	<i>H. Hy.</i>	Hepatic hypoblast.

<i>I. F.</i> Interamniotic foramen.	<i>S. M.</i> Spinal medulla.
<i>It. V.</i> Iter venosum.	<i>So.</i> Somatopleure.
<i>J. V.</i> Jugular vein.	<i>S.</i> Spleen.
<i>L.</i> Liver.	<i>Spl.</i> Splanchnopleure.
<i>Lng.</i> Lung.	<i>Spl'.</i> Hinder part of splanchnopleure.
<i>L. D.</i> Lateral portions of diaphragm.	<i>St.</i> Stomach.
<i>M.</i> Mouth.	<i>S. T.</i> Septum transversum.
<i>M. A.</i> Mandibular arch.	<i>S. R.</i> Sinus reuniens.
<i>M. B.</i> Mid brain.	<i>S. R. Vit. V.</i> Septal portion of right vitelline vein.
<i>M. L.</i> Mesocardium laterale.	<i>S. V.</i> Subelavian veins.
<i>Mes. Ant. and Post.</i> Mesocardium—posterior and laterale.	<i>T.</i> Tail.
<i>Mes. D. and V.</i> Mesentery—dorsal and ventral.	<i>Th. D.</i> Thoracic duct.
<i>M. V.</i> Mesenteric veins.	<i>Tr.</i> Trachea.
<i>Œs.</i> Œsophagus.	<i>Ut.</i> Uterus.
<i>P.</i> Peritoneal sac.	<i>U. V.</i> Umbilical vein.
<i>P. Am.</i> Pro-amnion.	<i>Ven.</i> Ventricle.
<i>P. C.</i> Pericardial cavity.	<i>V. D.</i> Ventral diaphragm.
<i>P. Div.</i> Pulmonary diverticulum.	<i>V. Ht.</i> Venous end of heart.
<i>P. M.</i> Peripheral unclleft mesoblast.	<i>Vit. V. R. and L.</i> Vitelline vein—right and left.
<i>P. N.</i> Pronephros.	<i>Vit. D.</i> Vitelline duct.
<i>P. P. C.</i> Pleuro-peritoneal cœlom.	<i>Vil. P.</i> Villous projections.
<i>Plac.</i> Placenta.	<i>V. C. S.</i> Vena cava superior.
<i>Pl.</i> Pleural cavity.	<i>V. C. I.</i> Vena cava inferior.
<i>P. V.</i> Pulmonary veins.	<i>W. B.</i> Wolffian body.
<i>R.</i> Apical recess.	<i>W. D.</i> Wolffian duct.
<i>R. Ab.</i> Recessus abdominalis.	<i>W. T.</i> Wolffian tubule.
<i>R. Pul.</i> Recessus pulmonalis.	

## DESCRIPTION OF FIGURES.

The addition of a letter to any number implies that those drawings were made from the same embryo or series of sections.

- Fig. 1. Rabbit. Commencement of eighth day.  
 Fig. 2. Rabbit. Middle of eighth day.  
 Fig. 3. Rabbit. Second half of eighth day.  
 Fig. 4. Rabbit. Beginning of ninth day, ventral aspect.

- Fig. 5. Rabbit. Nine days and four hours. Longitudinal section through the iter venosum.
- Fig. 6. Rabbit. Nine days and a half. Sinus reuniens receives umbilical vein, and latter receives the jugular or anterior cardinal vein.
- Figs. 7A to 14A. Longitudinal sections of Rabbit's embryo at beginning of ninth day. This series demonstrates the continuity of the cardiac and pleuro-peritoneal cœlom behind the vitelline veins, and also the opening of the umbilical vein into the vitelline.
- Figs. 15B to 19B. Transverse sections of Rabbit's embryo of nine days and four hours. This embryo closely resembled fig. 4. The series consisted of 153 sections. 15B = sec. 19. 16B = sec. 44. 17B = sec. 57. 18B = sec. 77. 19B = sec. 139.
- Figs. 20C to 22C. Coronal sections of Rabbit's embryo of nine days and five hours :—
- 20C. Through iter venosum.
  - 21C. Through sinus-reuniens.
  - 22C. Through septum transversum and liver.
- Figs. 23D to 30D. Rabbit's embryo of second half of ninth day. Liver, placenta, course of veins, and relation of embryo to wall of uterus (after it has undergone rotation).
- Fig. 30. Placental region of Rabbit beginning of tenth day.
- Fig. 31. Coronal section through Rabbit's embryo at beginning of tenth day. The relation of embryo to wall of uterus and placental region, especially the relation of placental region to hinder part of the splanchnopleure.
- Figs. 32E to 34E. Longitudinal sections of Rabbit's embryos of nine days and sixteen hours.
- 32E. Through iter venosum.
  - 33E. Through Cuvierian duct, jugular and posterior cardinal veins, umbilical vein, and sinus reuniens. An arrow has been placed in the iter venosum.
  - 34E. Relation of umbilical vein to duct of CUVIER (through outer wall of iter venosum).
- Fig. 35. Coronal section of Rabbit's embryo of fourteen days, to show the dorsal diaphragm.
- Fig. 36. Almost transverse section through Rabbit's embryo of nine days and sixteen hours at level of Cuvierian duct and iter venosum. The villous projections of the liver and venter are shown.
- Figs. 37F to 44F. Transverse sections of Rabbit's embryo of latter part of tenth day, to show sinus reuniens and septum transversum, liver, and great veins.
- Fig. 45. Coronal section of embryo of latter part of tenth or eleventh day, to show great veins and commencement of dorsal diaphragm.
- Fig. 46. Early Human embryo. Transverse section through Cuvierian duct and iter venosum.

## 384 PROFESSOR C. B. LOCKWOOD ON THE PERICARDIUM AND DIAPHRAGM.

Figs. 47G to 52G. Transverse section through Rabbit's embryo of twelve and a half days, to show the closure of the iter venosum and the development of the dorsal diaphragm.

Fig. 53. Human embryo 21 days (?). Showing the dorsal pericardium and ventral diaphragm.

Figs. 54H and 55H. Longitudinal section of Rabbit's embryo of twelve and a half days.

54H. Great veins, dorsal pericardium, and ventral diaphragm.

55H. Commencement of dorsal diaphragm.

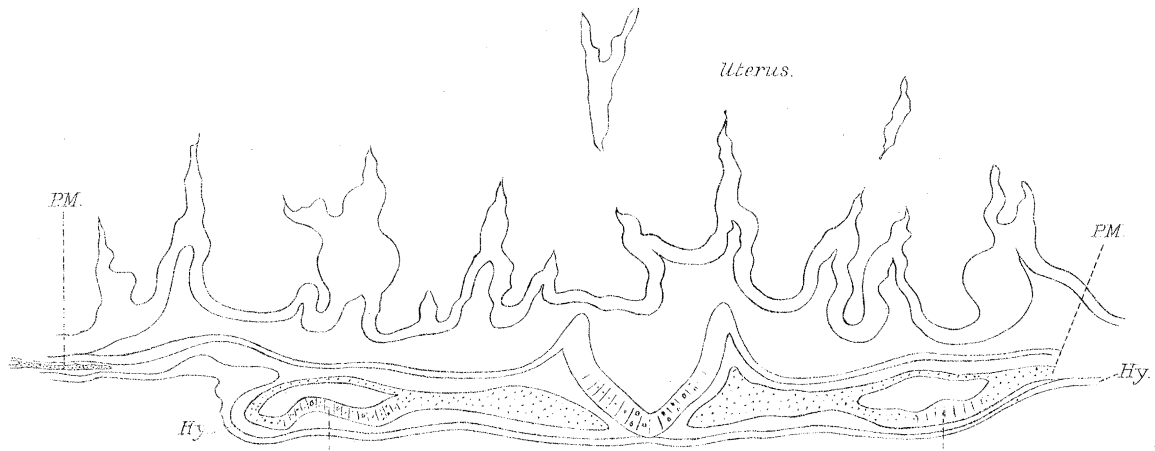
Fig. 56. Transverse section of Human embryo. Dorsal diaphragm and dorsal pericardium.

Figs. 57I to 61I. Rabbit's embryo of thirteen days. Pulmonary veins, diaphragm, and pericardium.

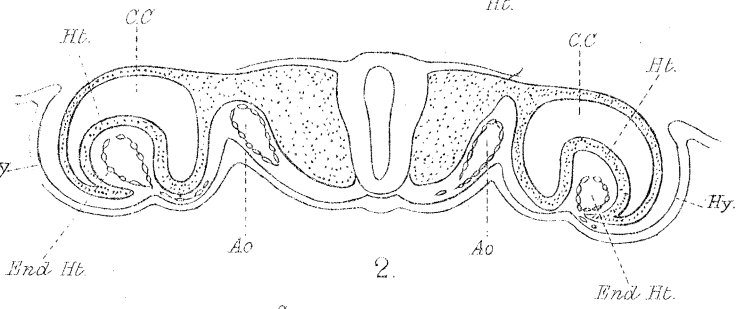
Fig. 62. Rabbit's embryo. Pulmonary veins and pericardium.

Figs. 63J and 64J. Human embryo. Relation of dorsal diaphragm to the liver and ventral diaphragm.

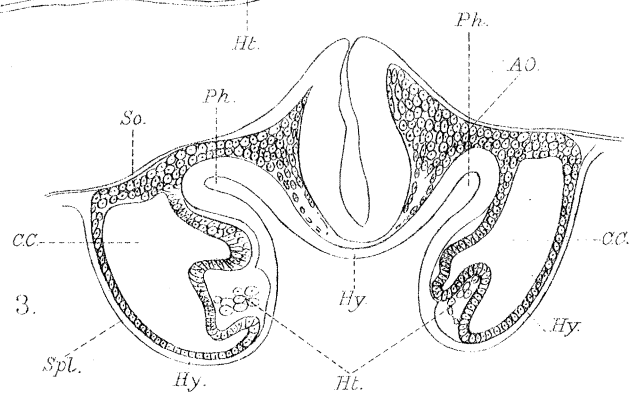
PHILOSOPHICAL TRANSACTIONS OF THE ROYAL SOCIETY OF BIOLOGICAL SCIENCES



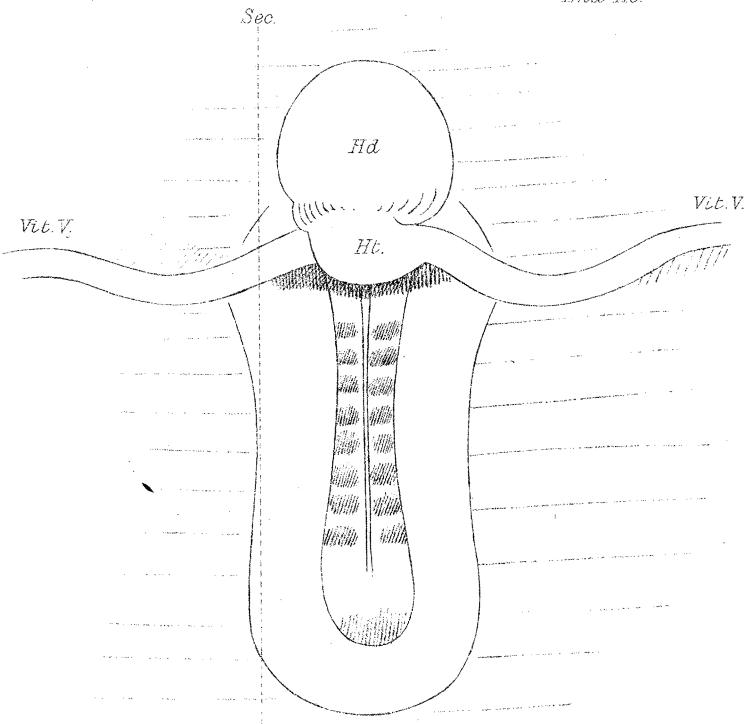
1.



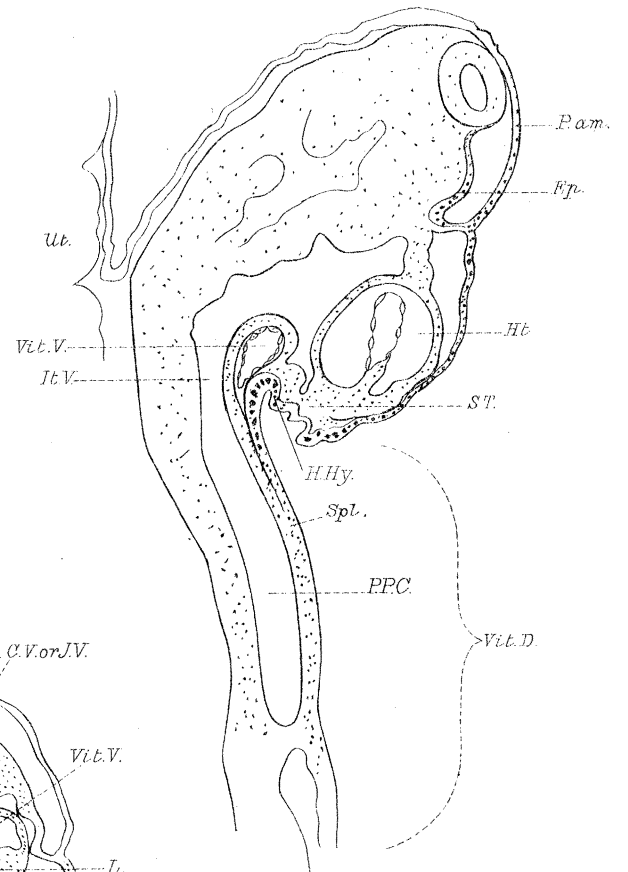
2.



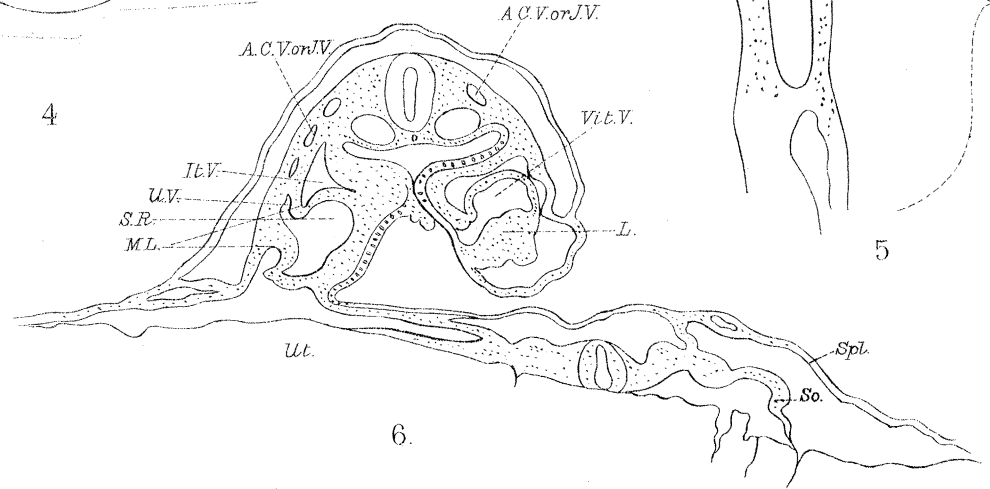
3.



4.



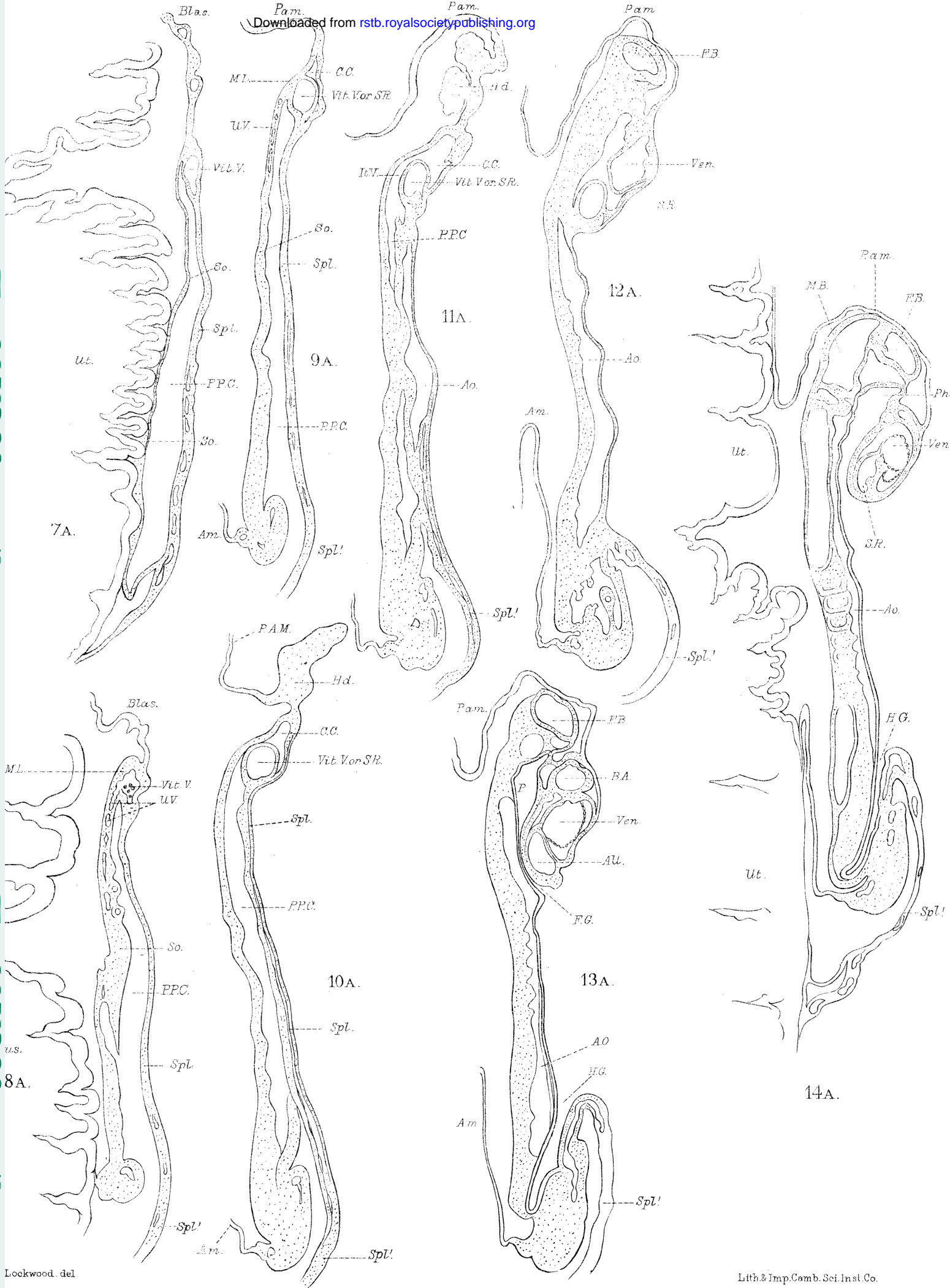
5.

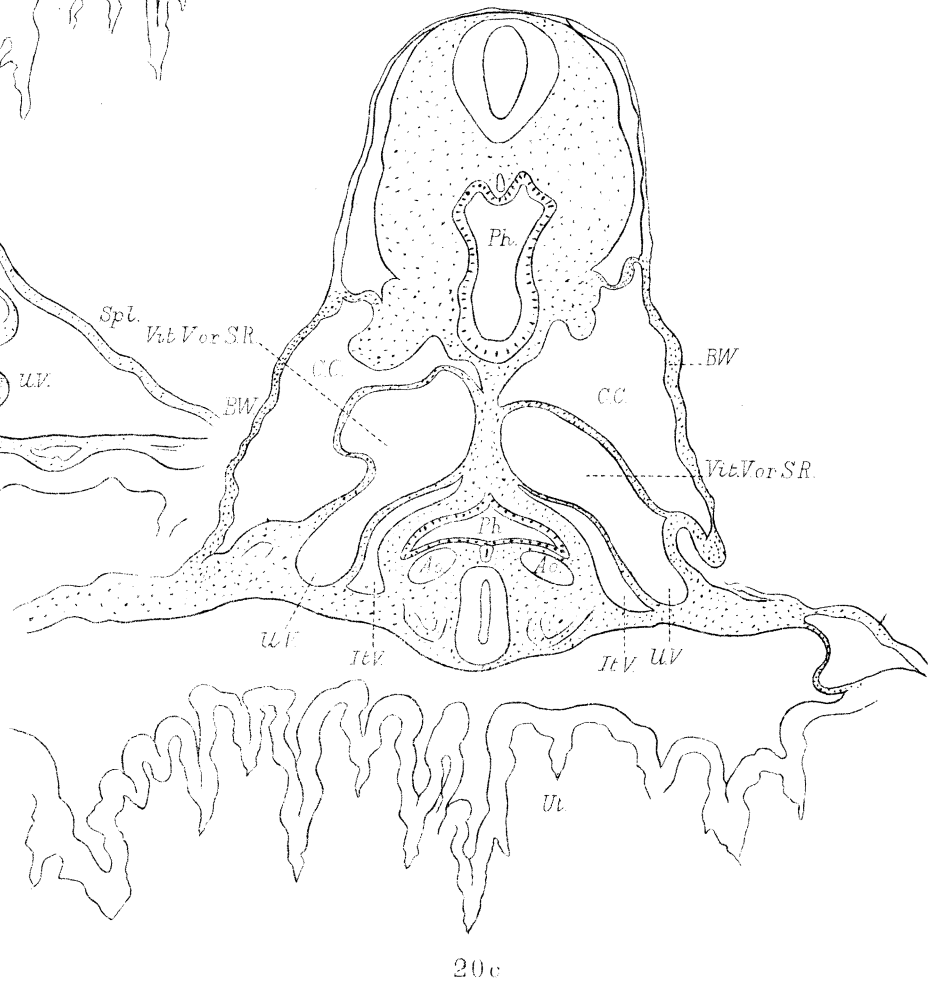
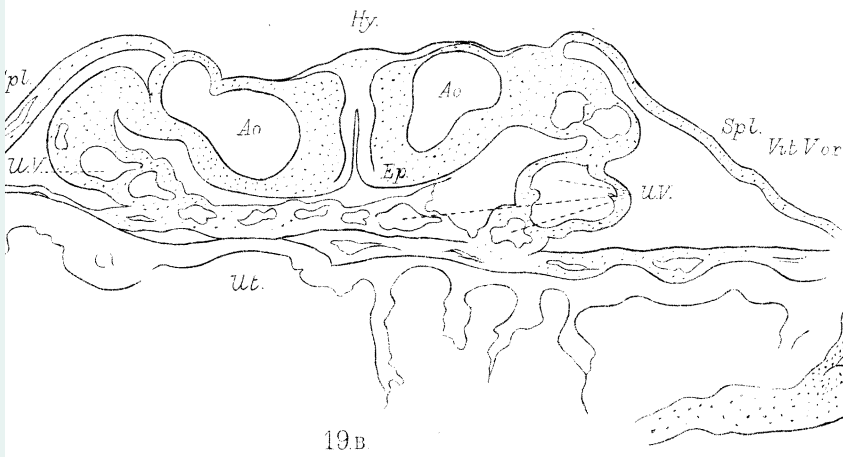
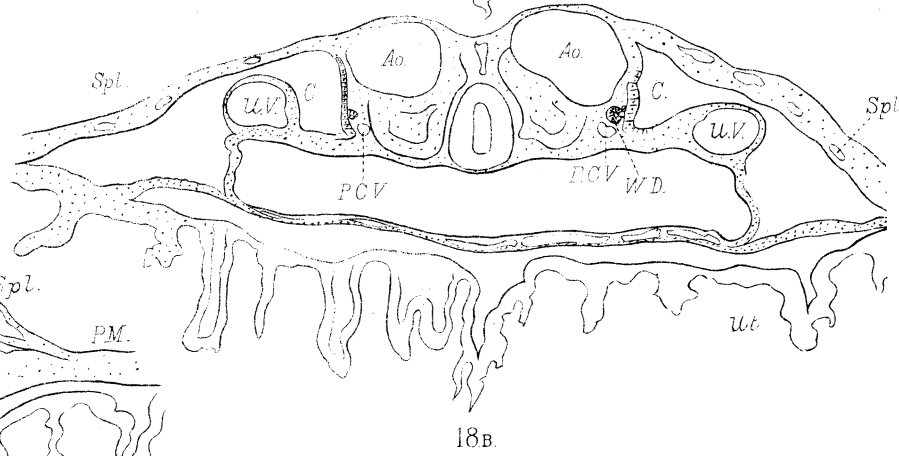
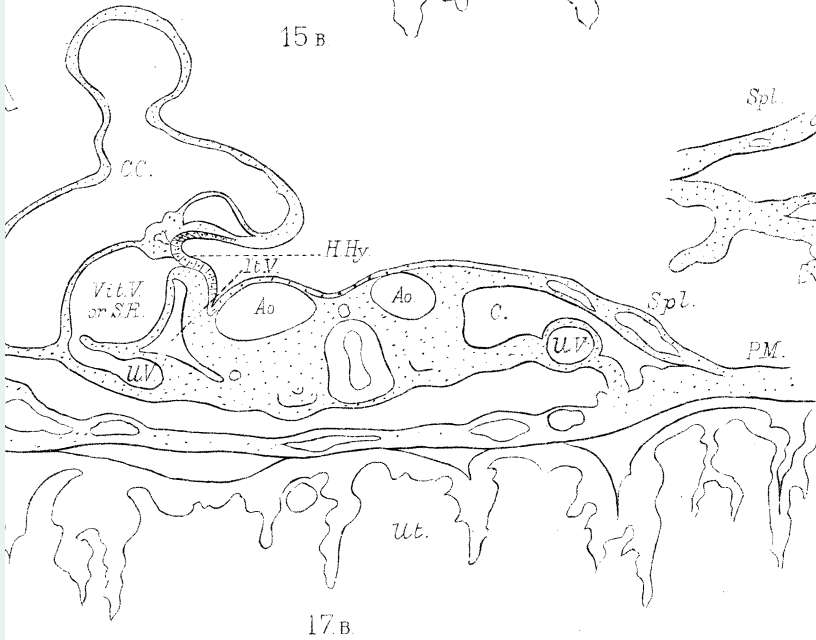
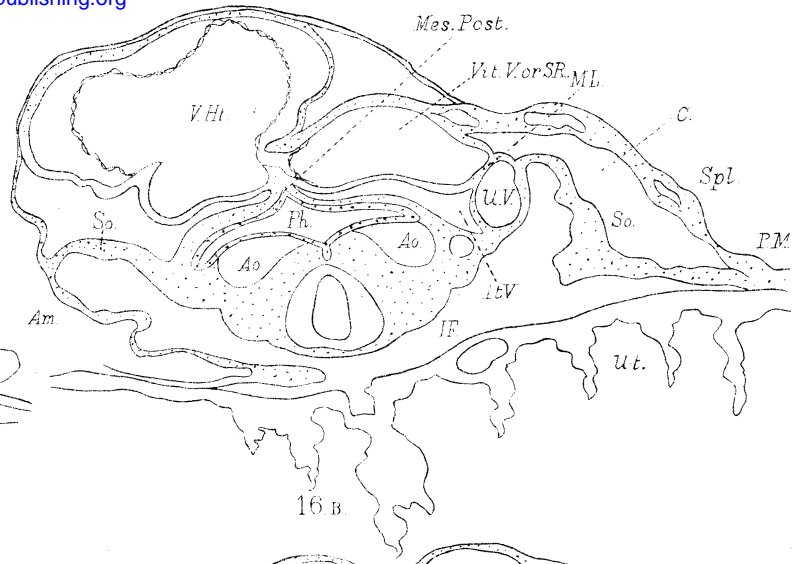
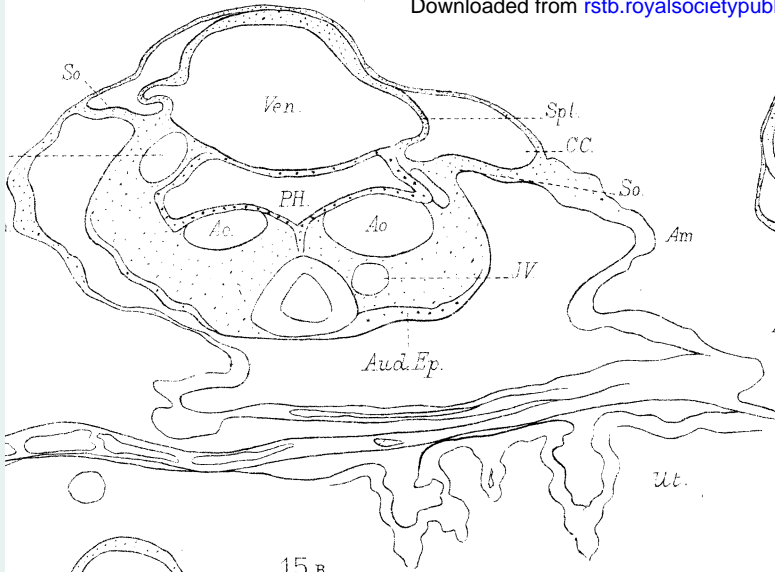


6.

PHILOSOPHICAL THE ROYAL BIOLOGICAL SOCIETY OF TRANSACTIONS SCIENCES

Downloaded from [rstb.royalsocietypublishing.org](http://rstb.royalsocietypublishing.org)



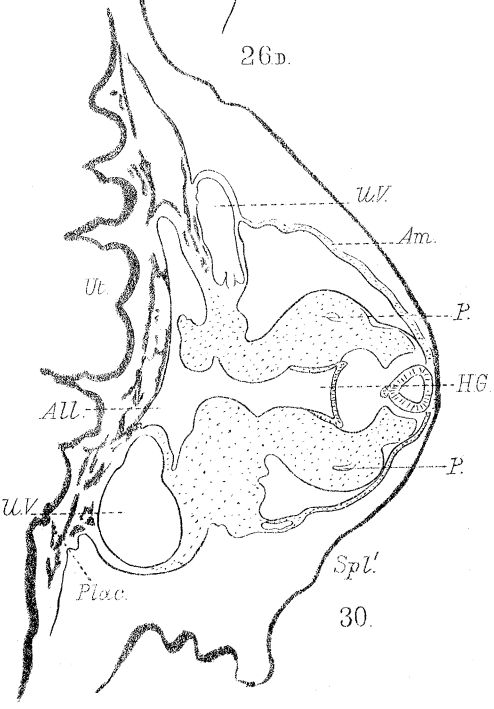
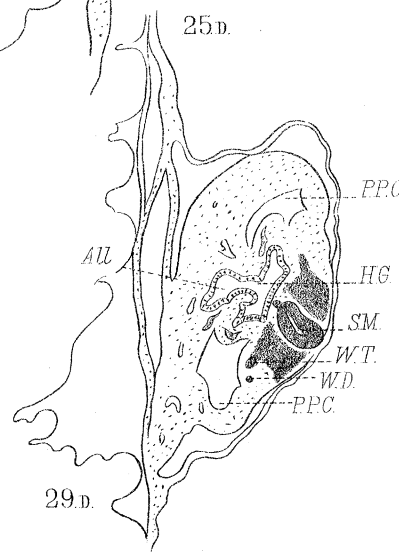
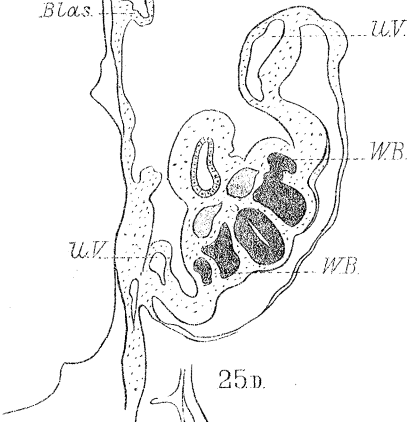
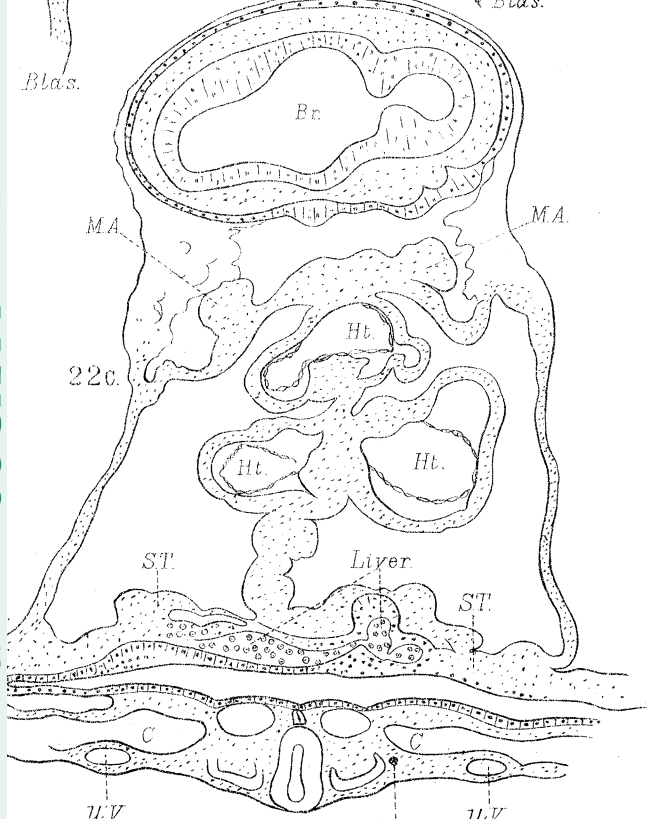
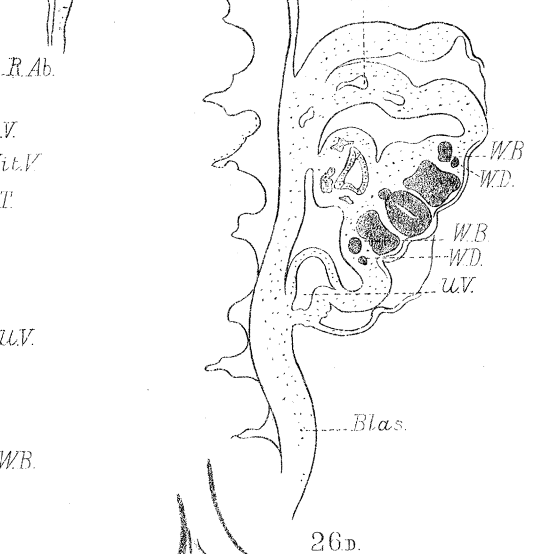
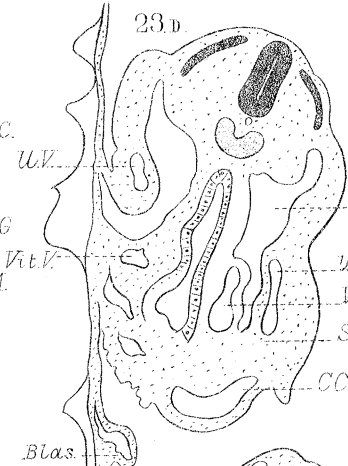
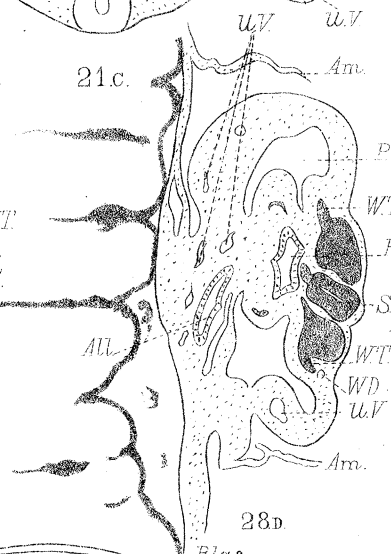
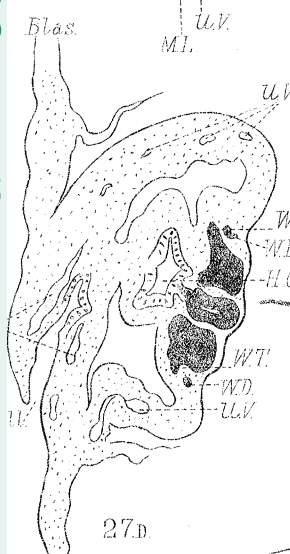
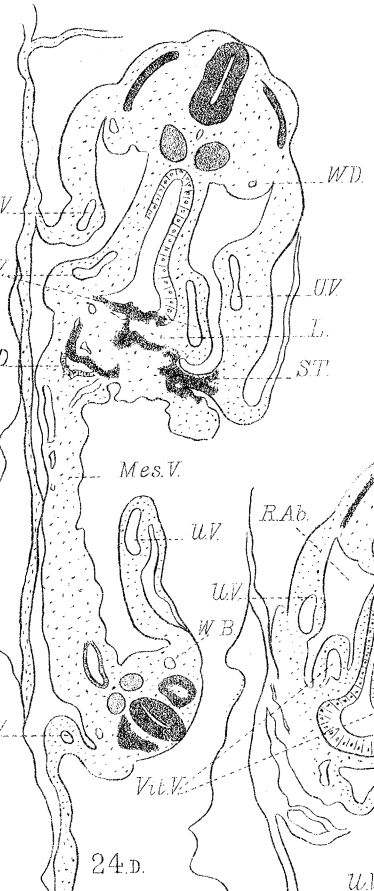
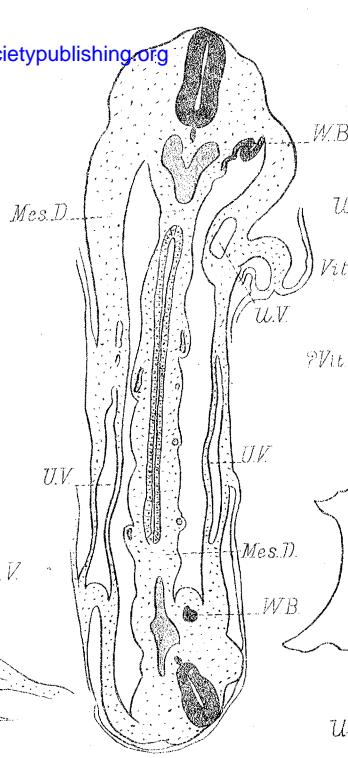
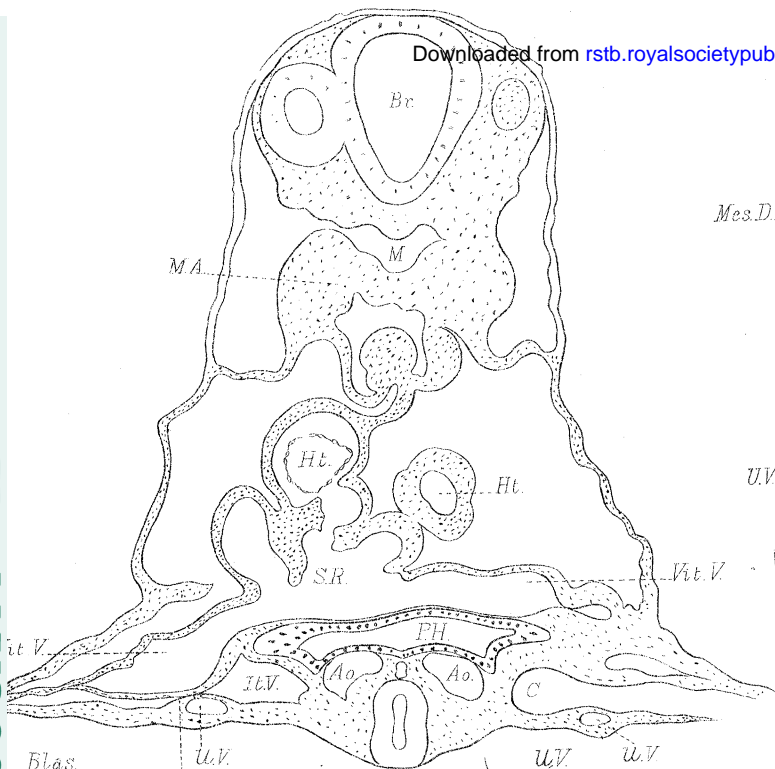


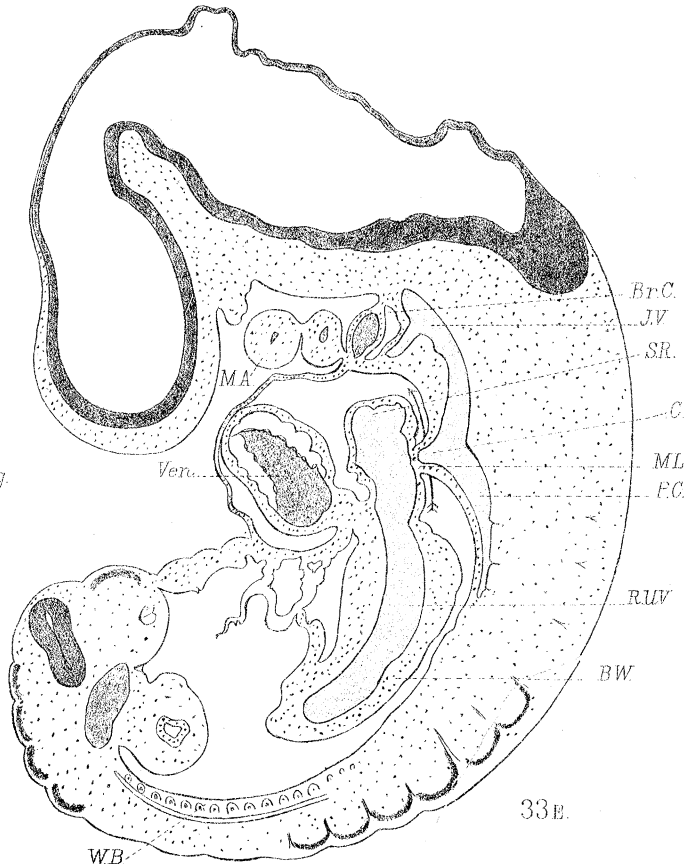
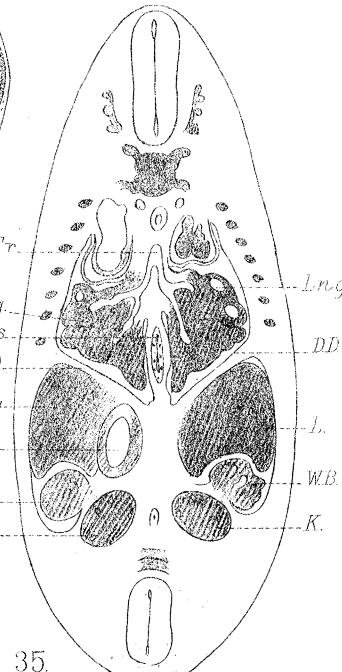
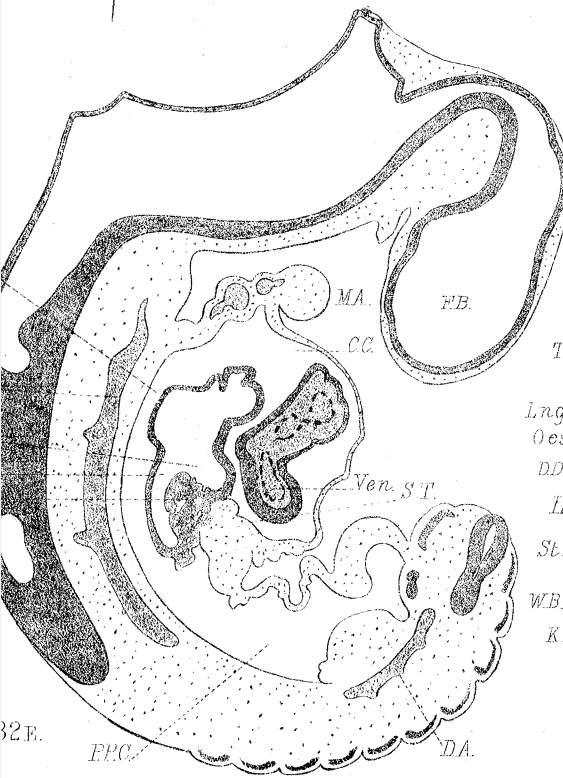
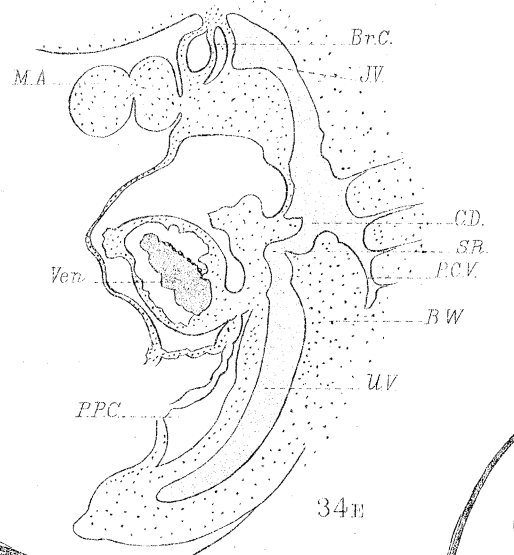
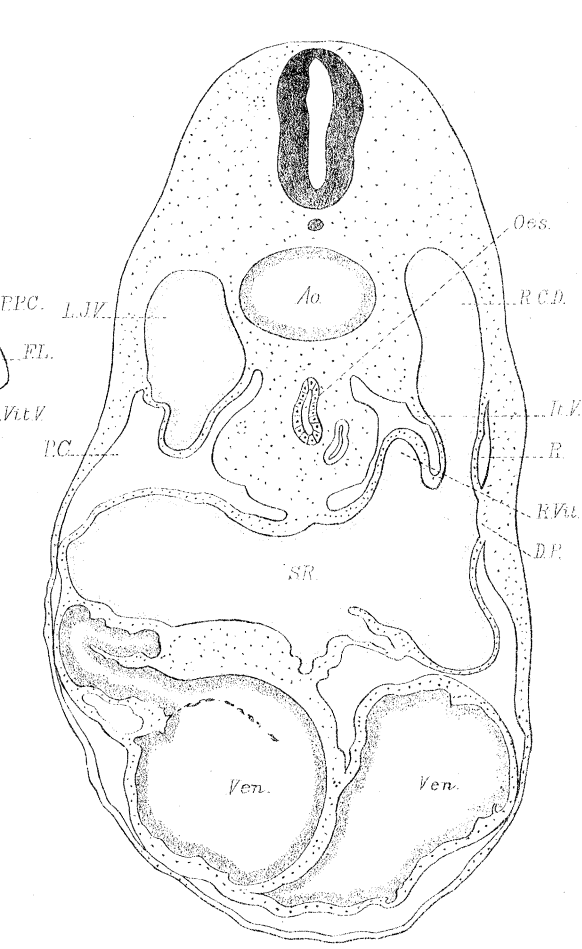
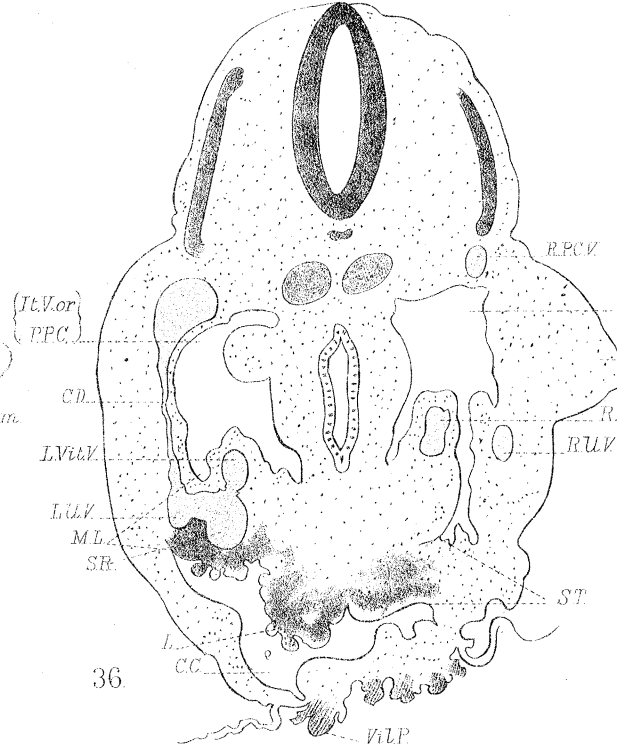
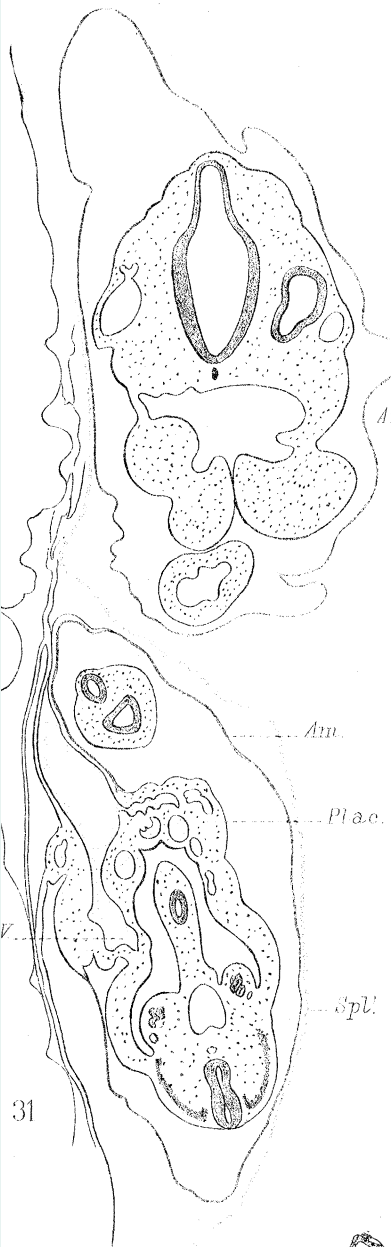
BIOLOGICAL SCIENCES  
 THE ROYAL SOCIETY OF  
 PHILOSOPHICAL TRANSACTIONS OF

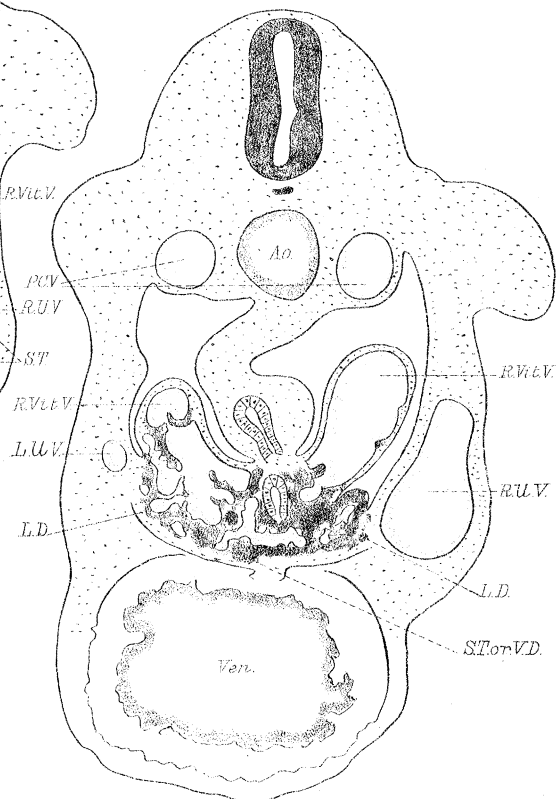
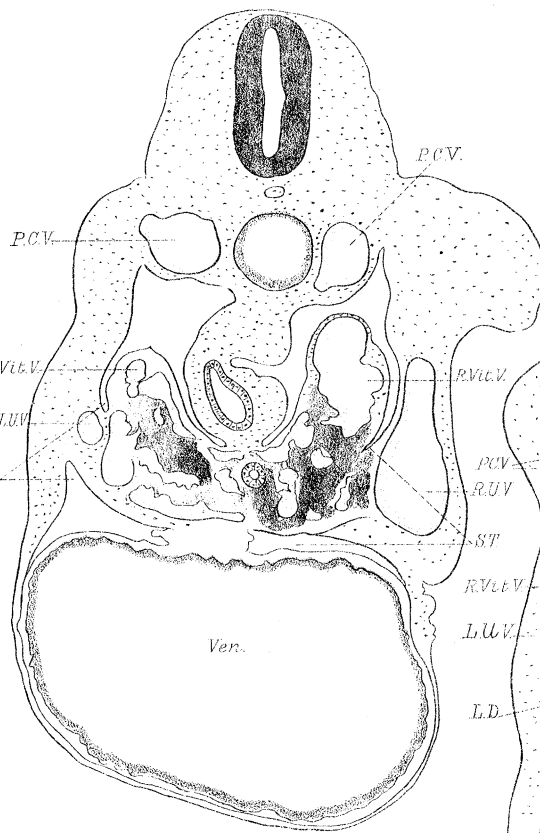
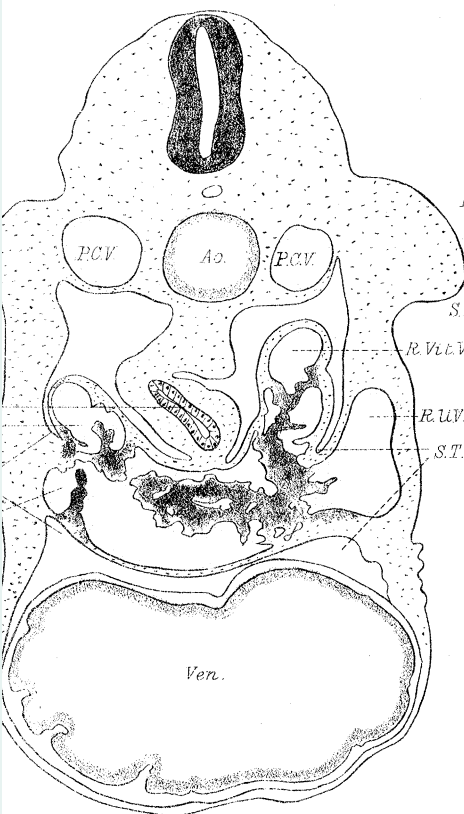
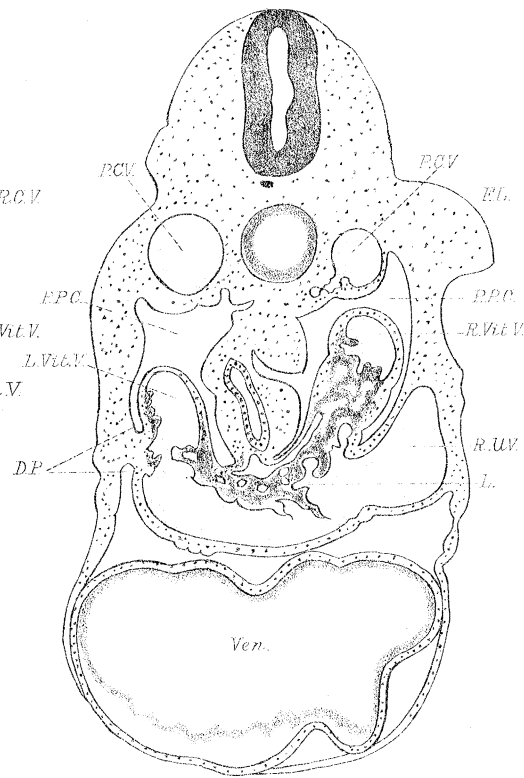
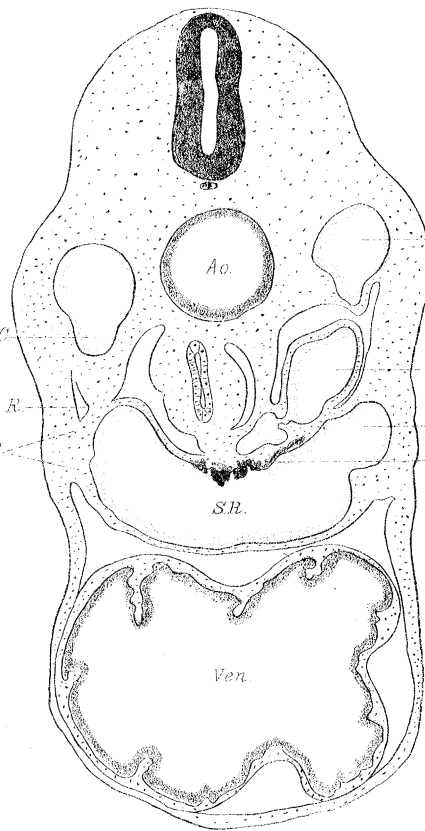
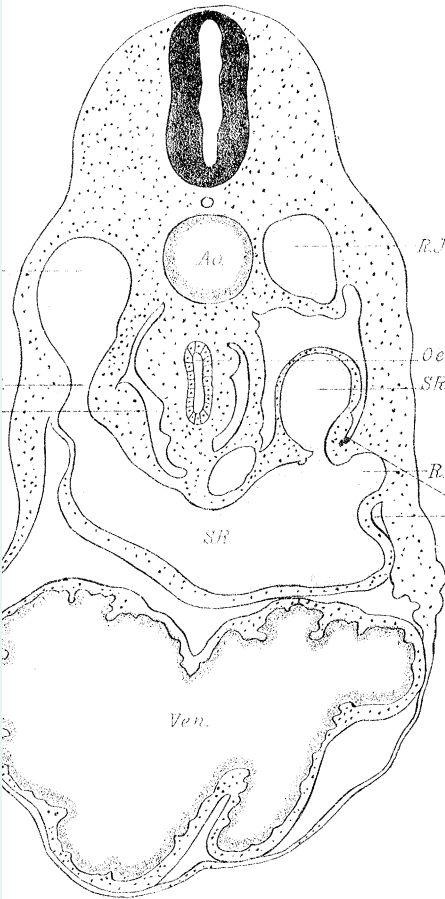

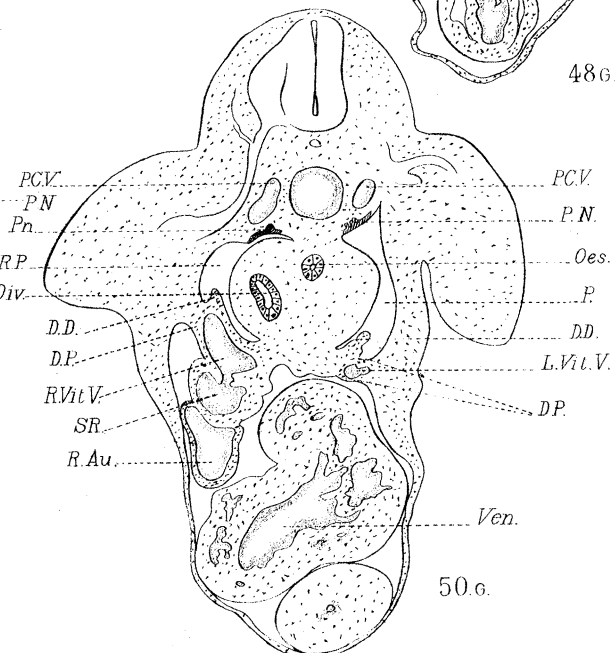
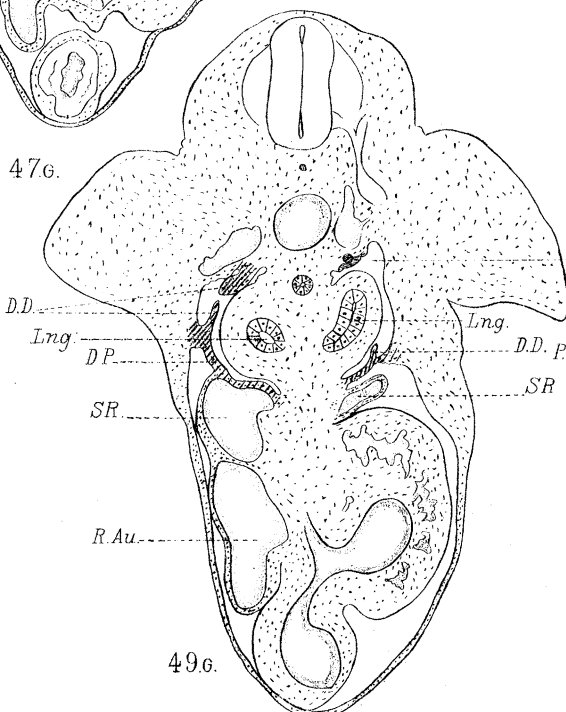
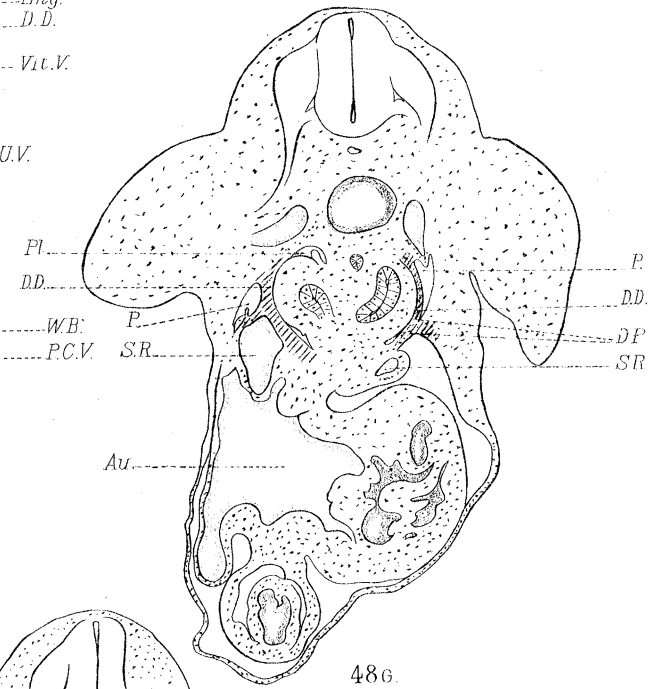
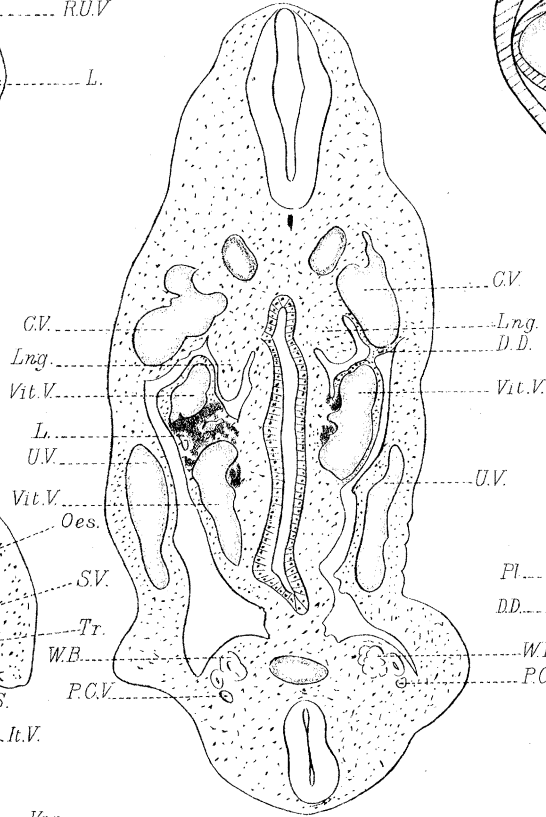
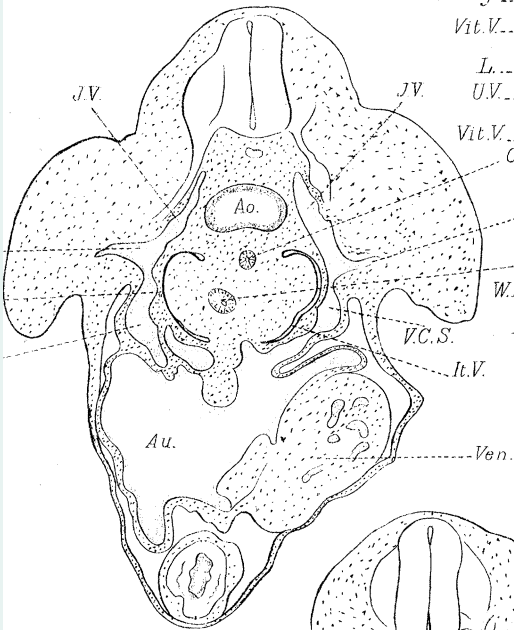
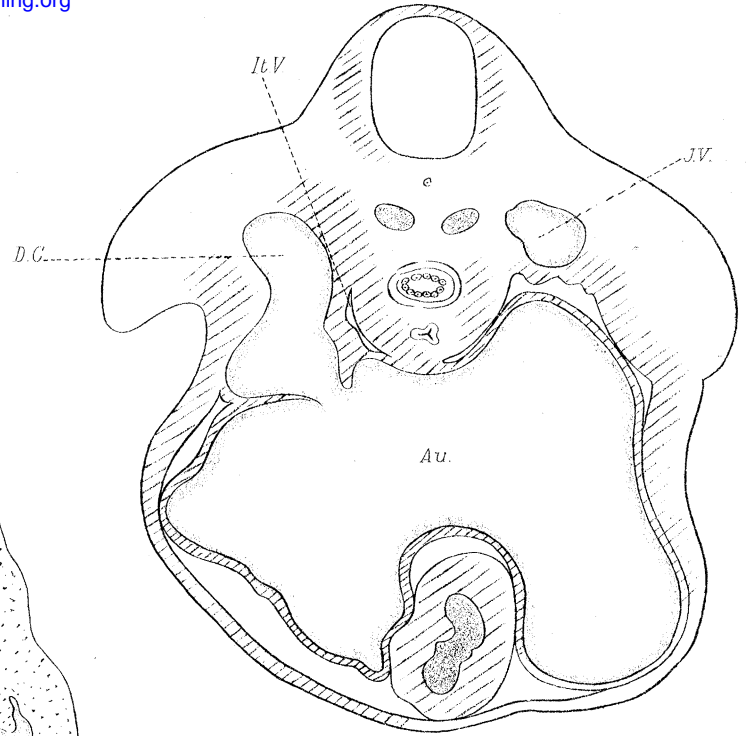
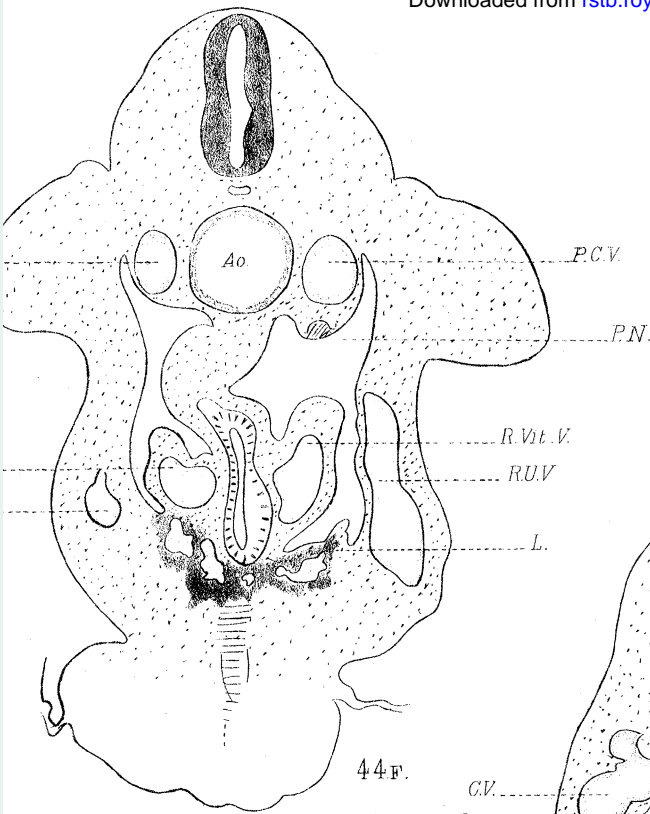
PHILOSOPHICAL THE ROYAL BIOLOGICAL TRANSACTIONS SOCIETY OF SCIENCES

Downloaded from [rstb.royalsocietypublishing.org](http://rstb.royalsocietypublishing.org)



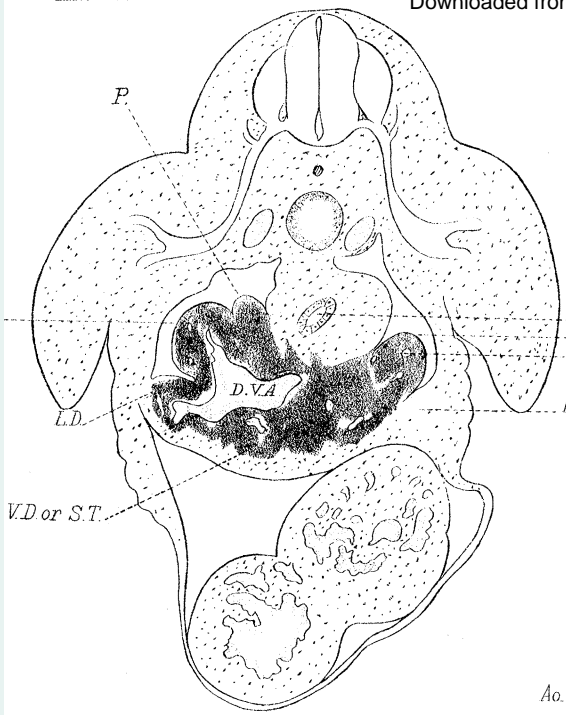




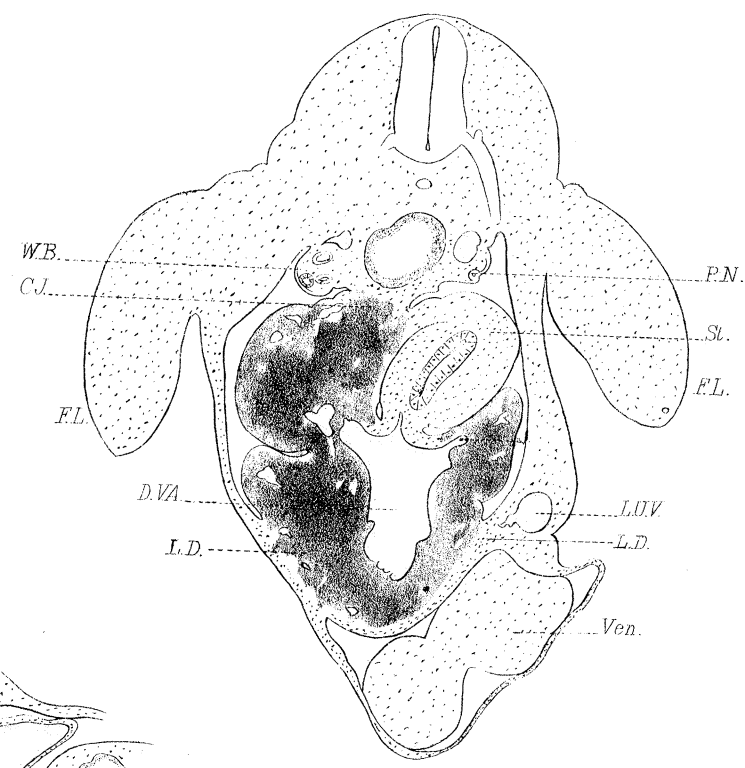


PHILOSOPHICAL THE ROYAL SOCIETY OF TRANSACTIONS OF BIOLOGICAL SCIENCES

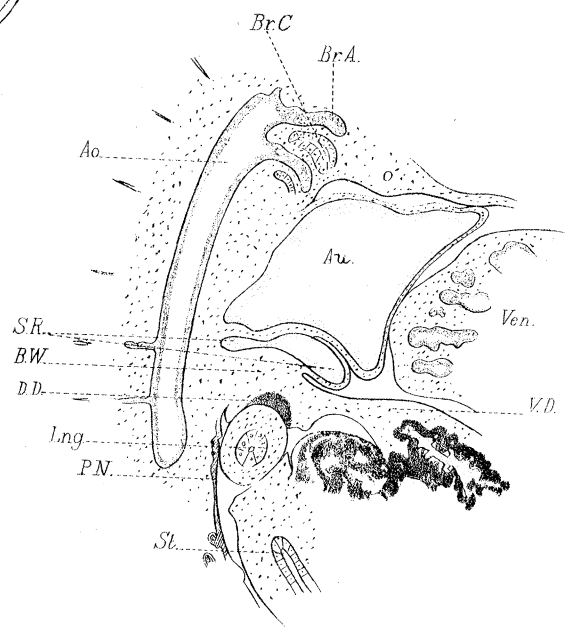
PHILOSOPHICAL THE ROYAL SOCIETY OF TRANSACTIONS OF BIOLOGICAL SCIENCES



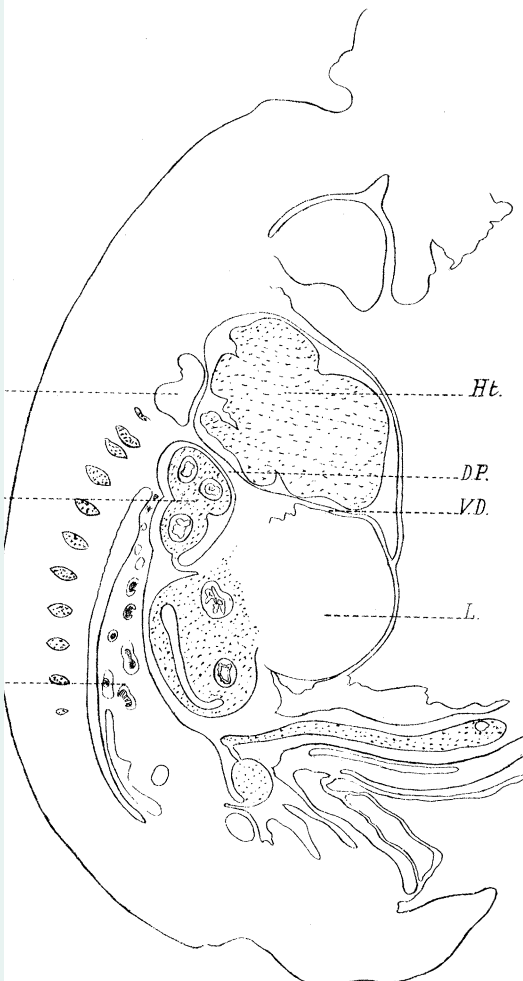
51.e.



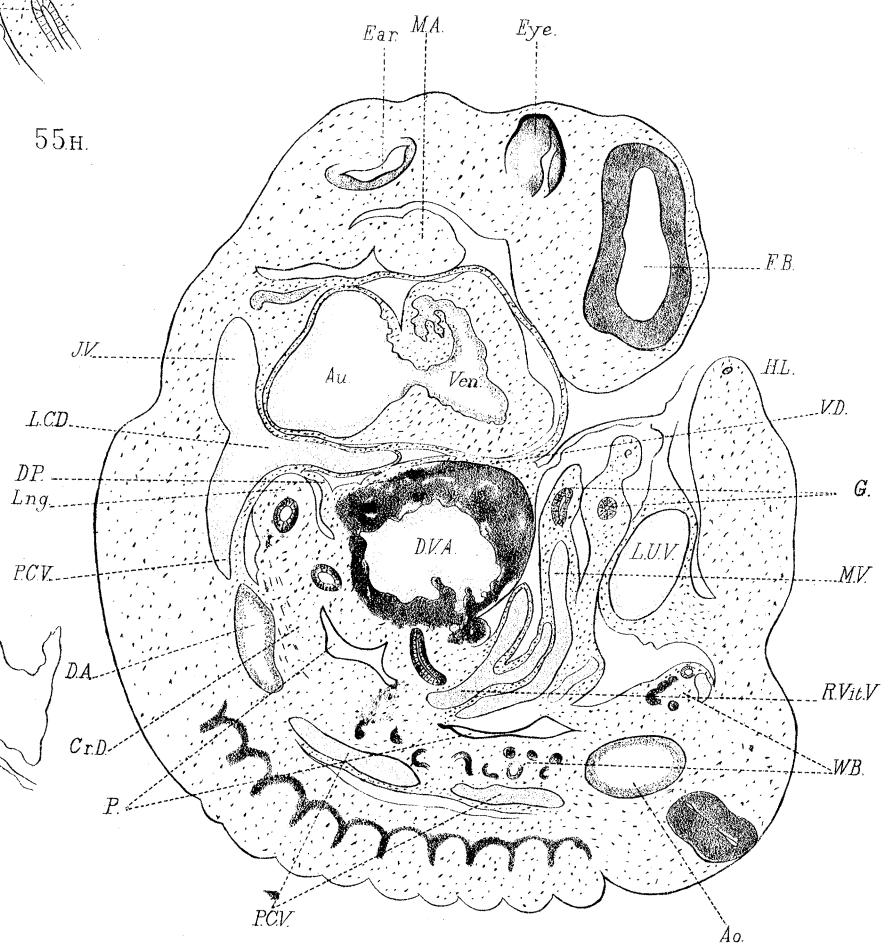
52.g.



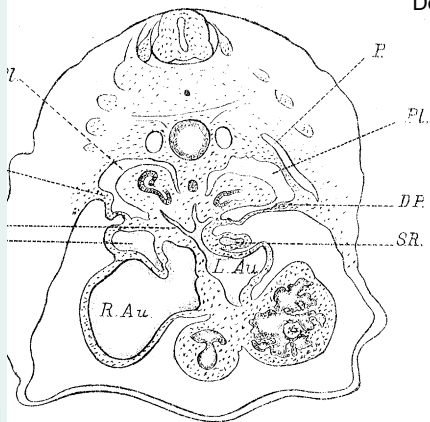
55.H.



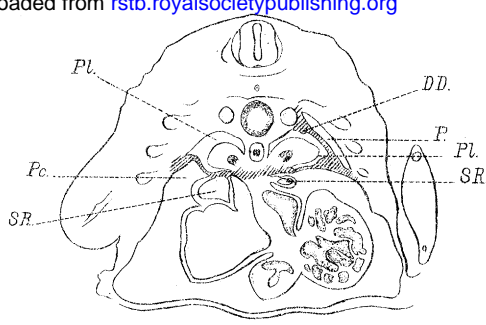
53.



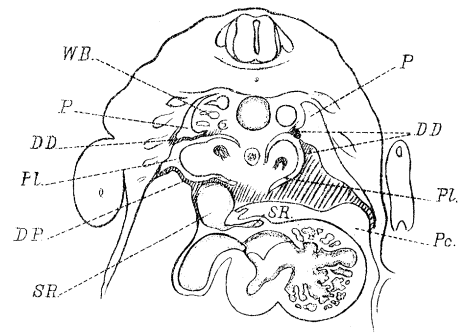
54.H.



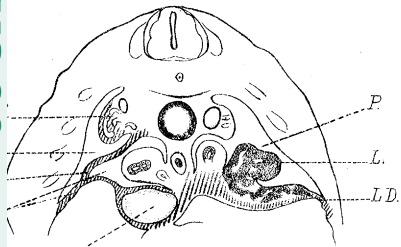
57.I.



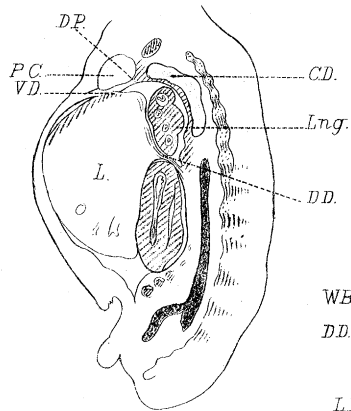
58.I.



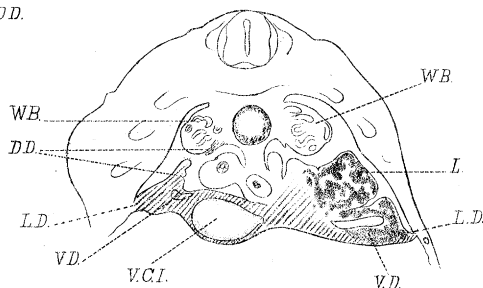
59.I.



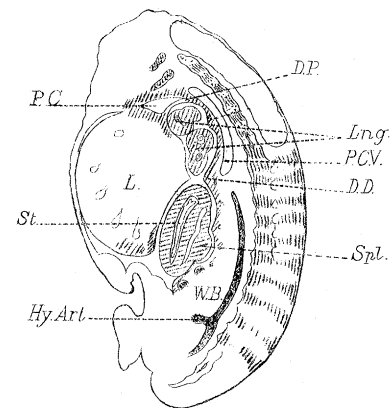
60.I.



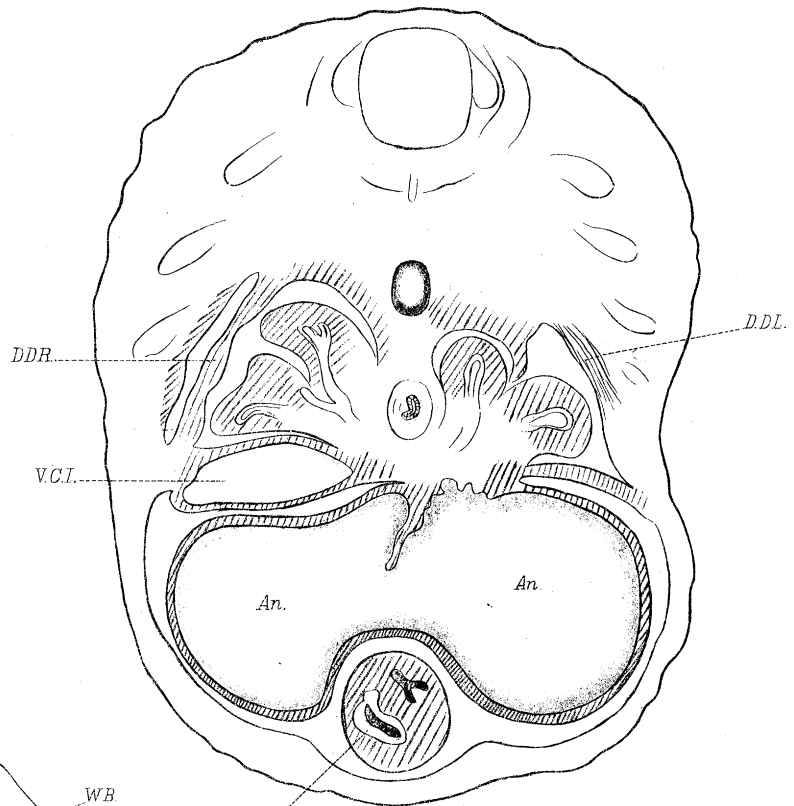
63.J.



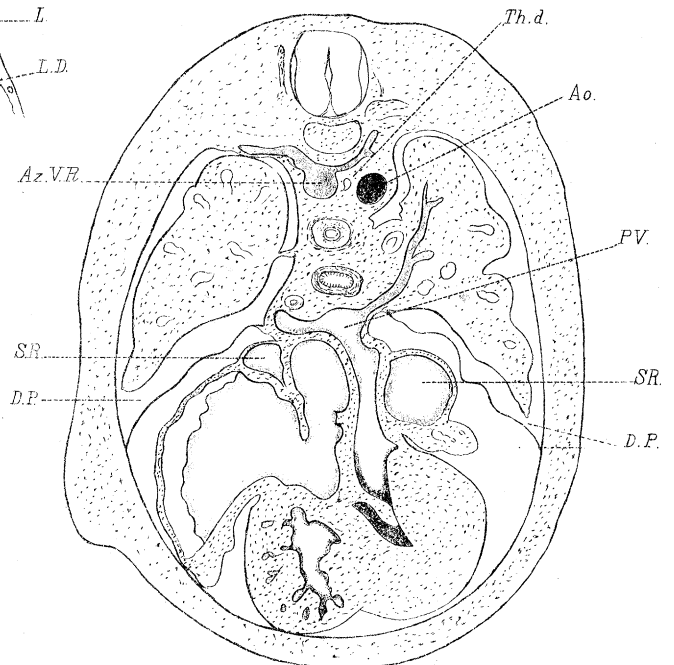
61.I.



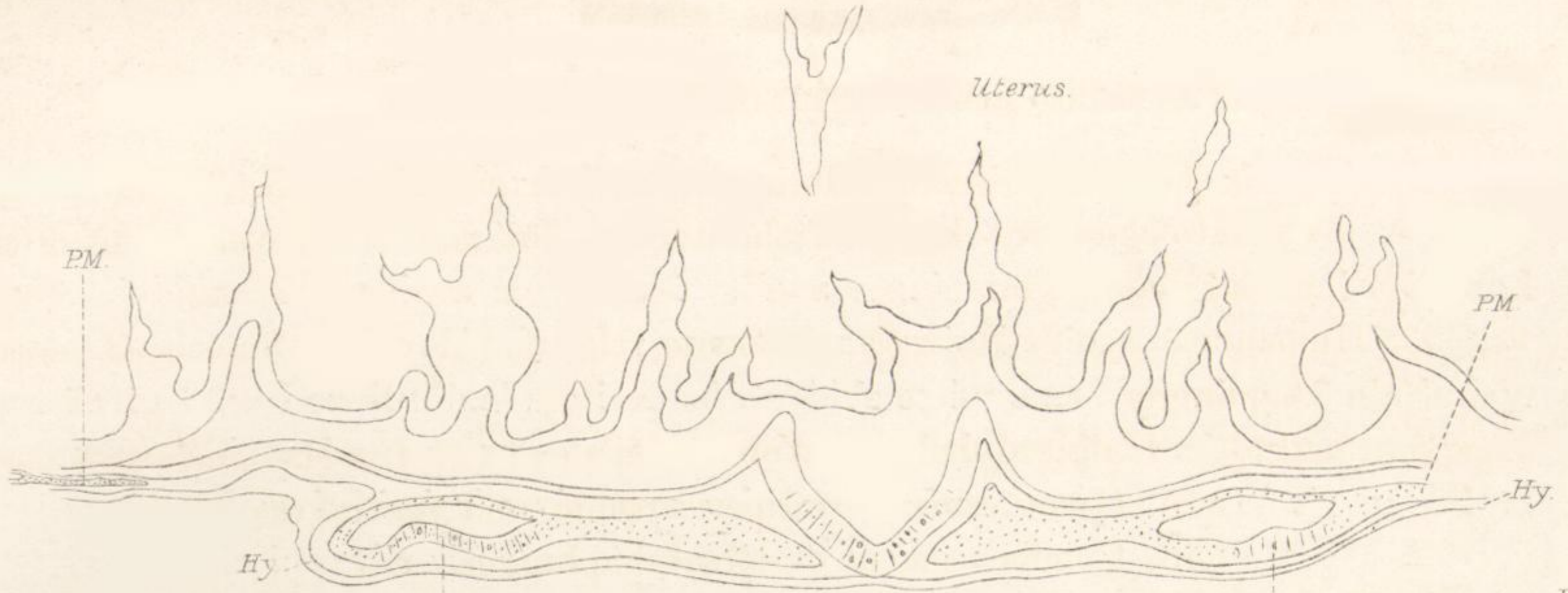
64.J.



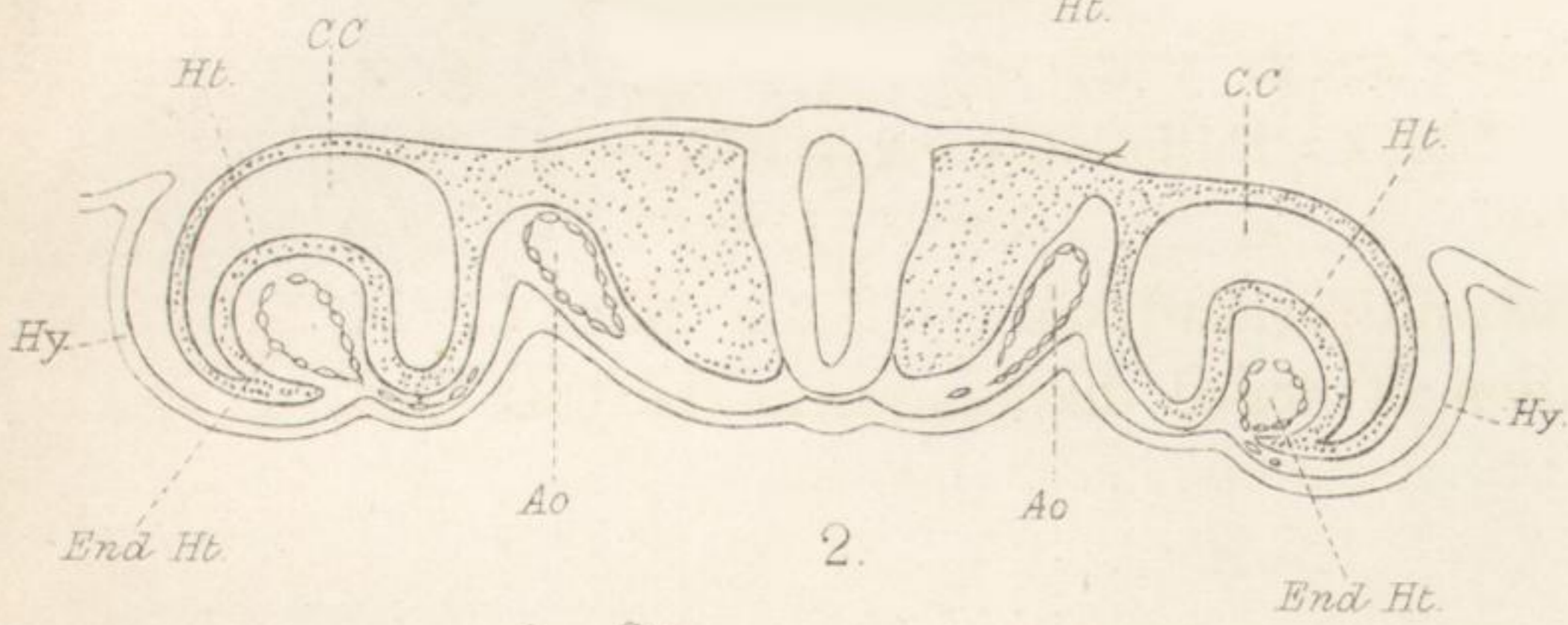
56.



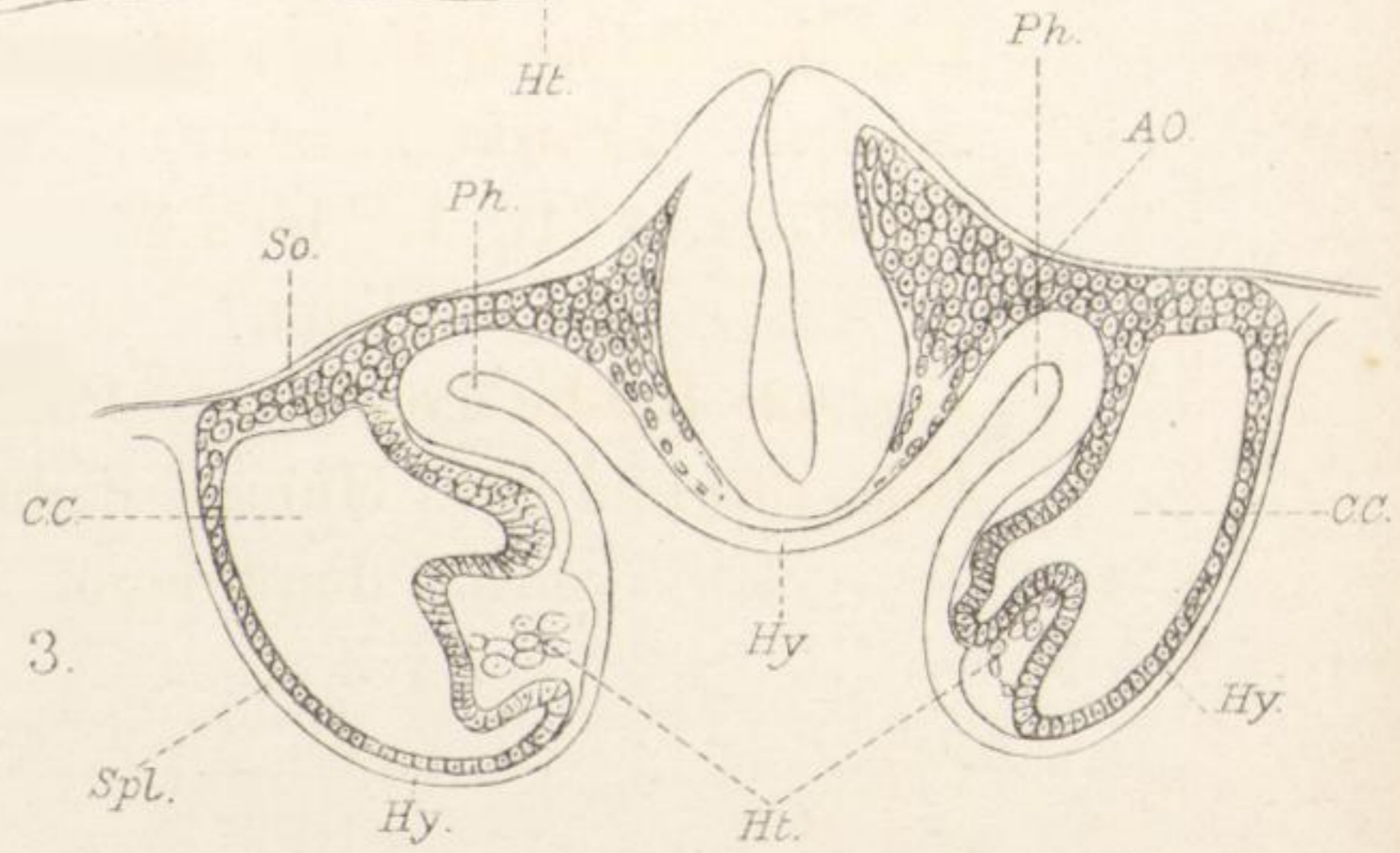
62.



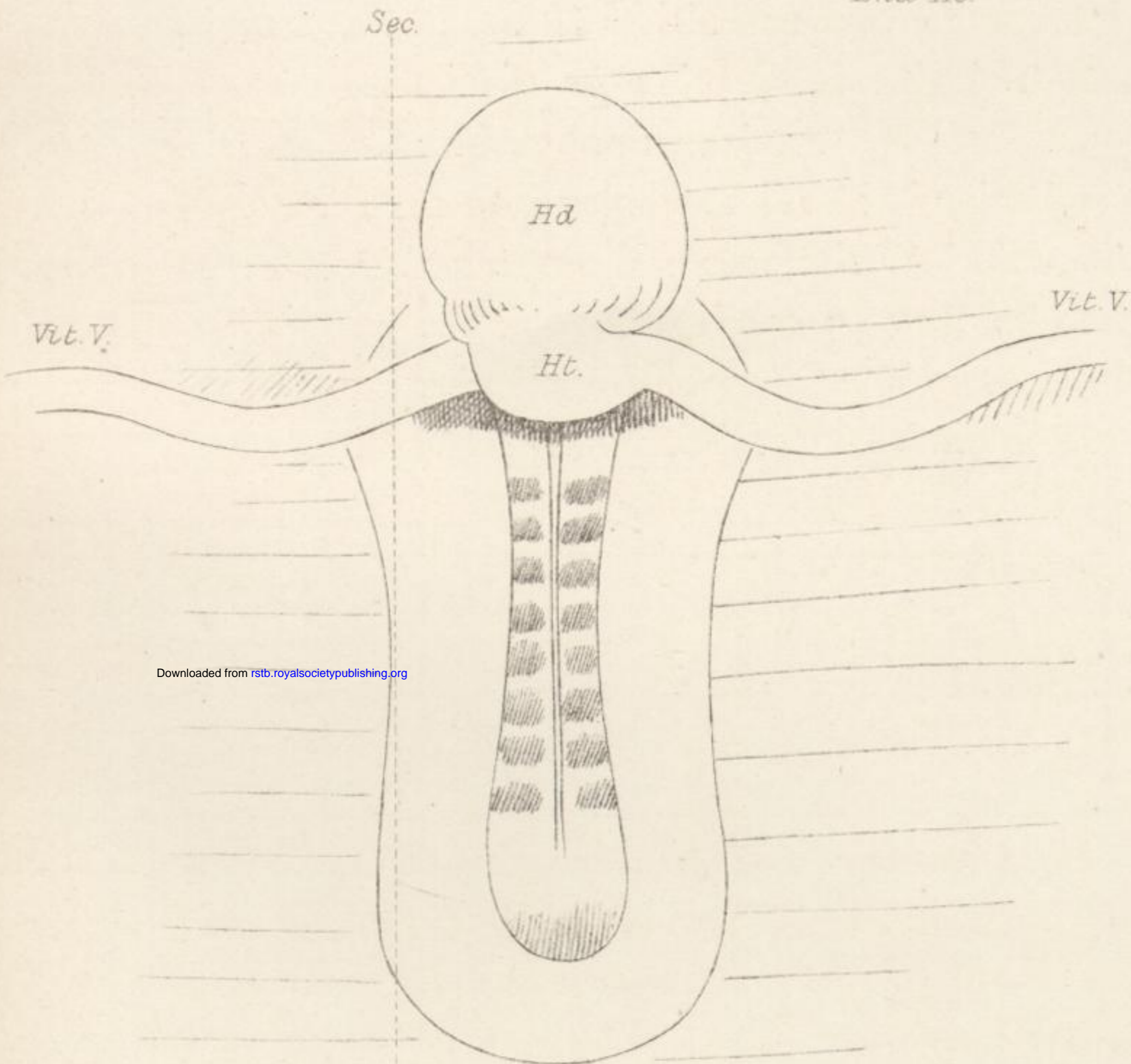
1.



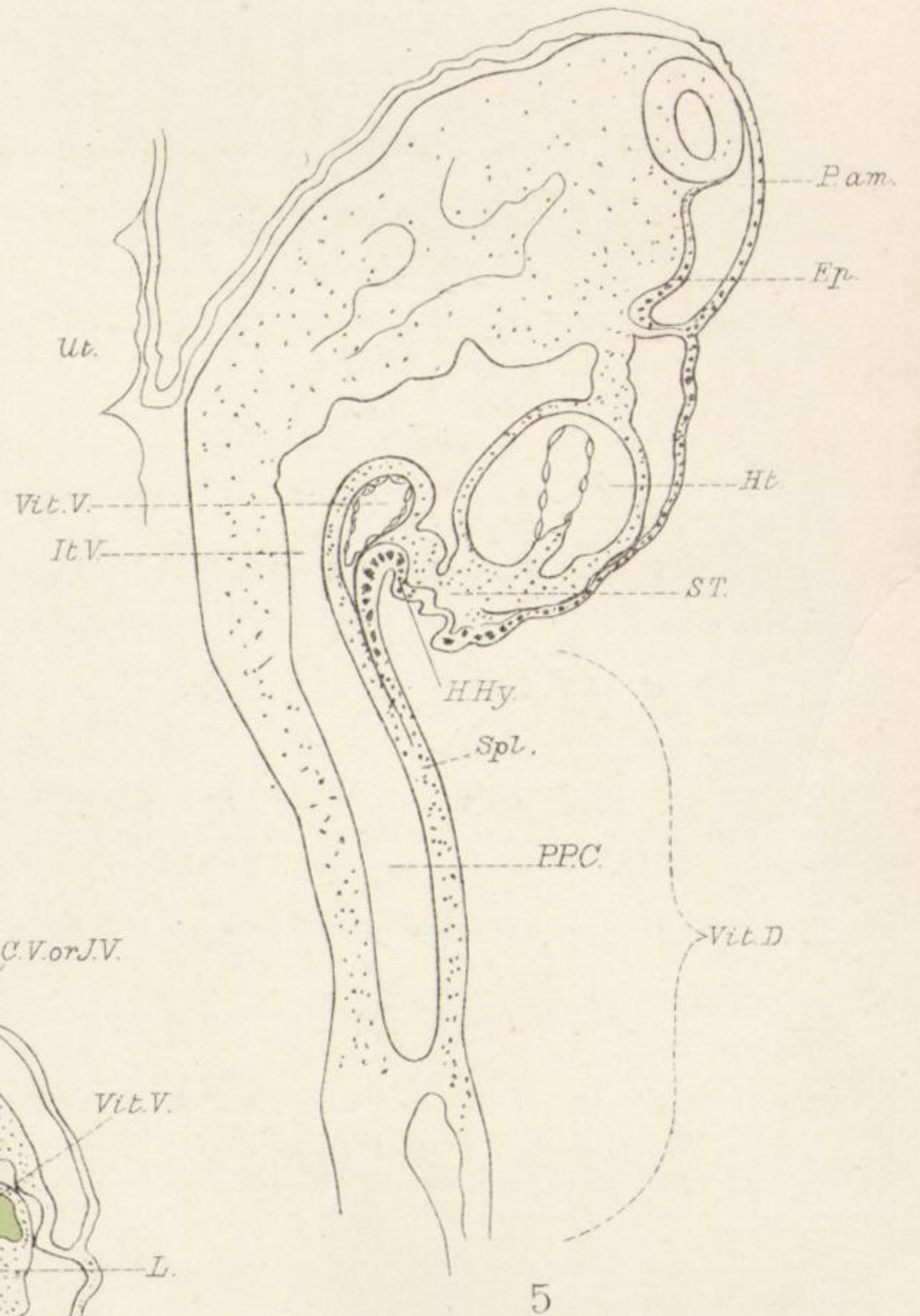
2.



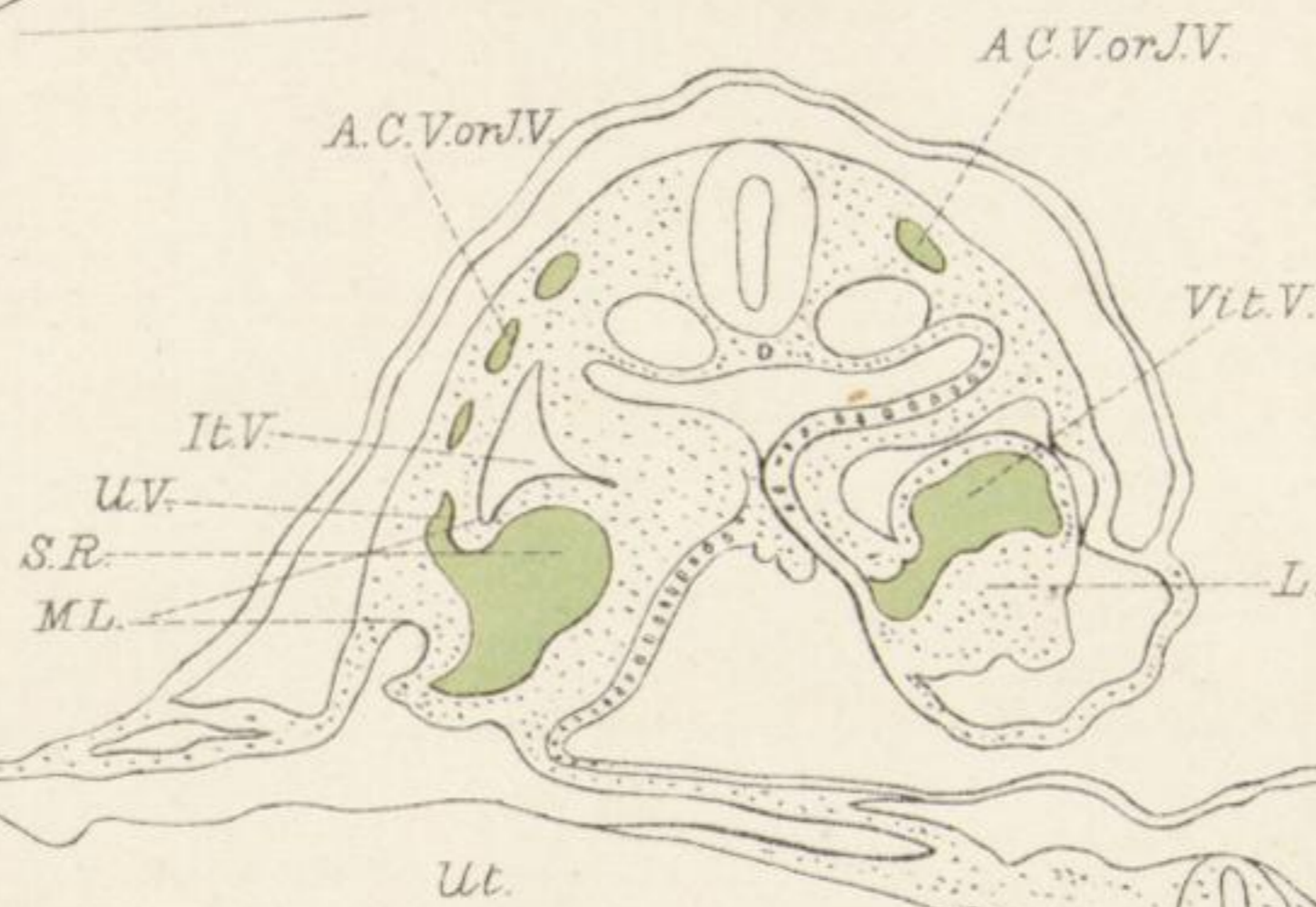
3.



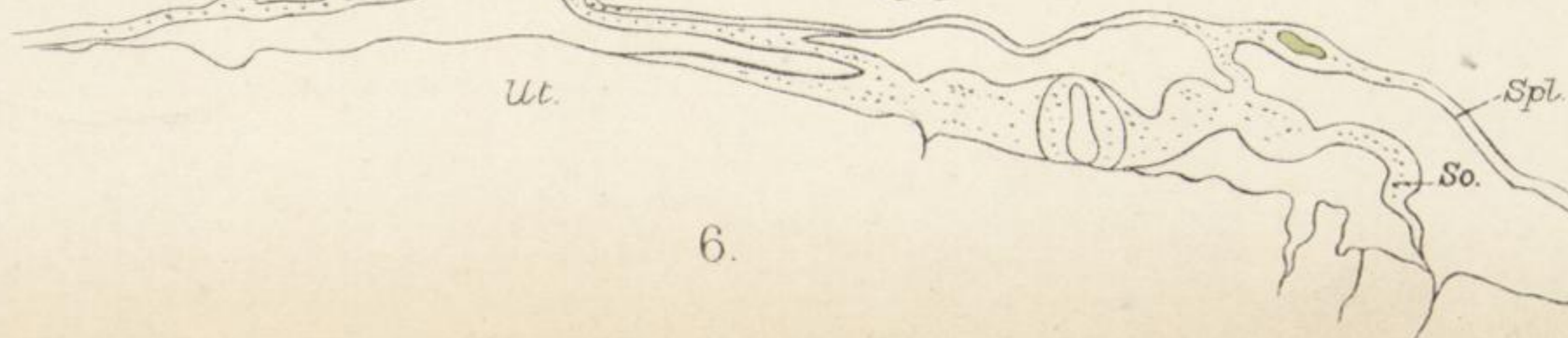4.

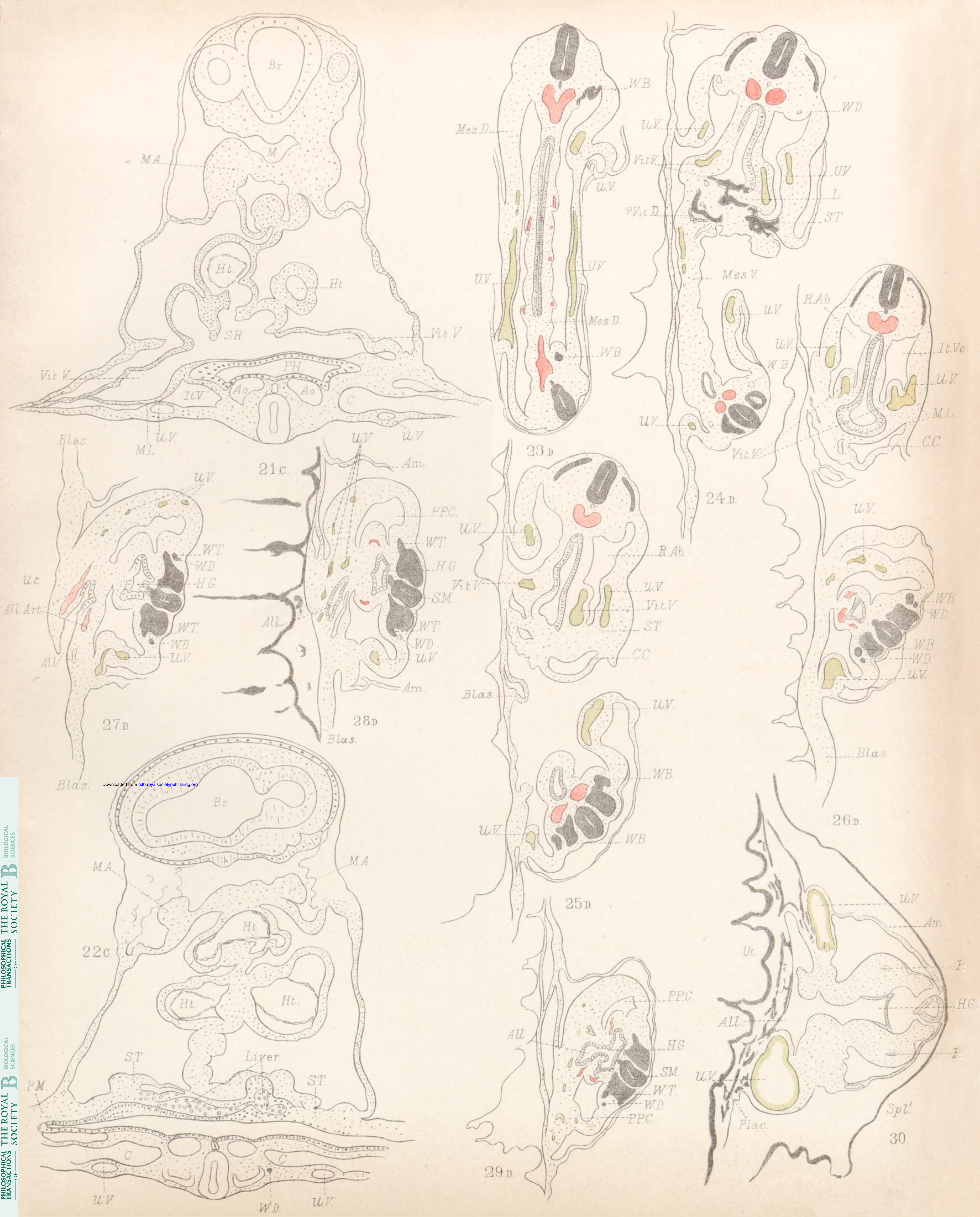


5.



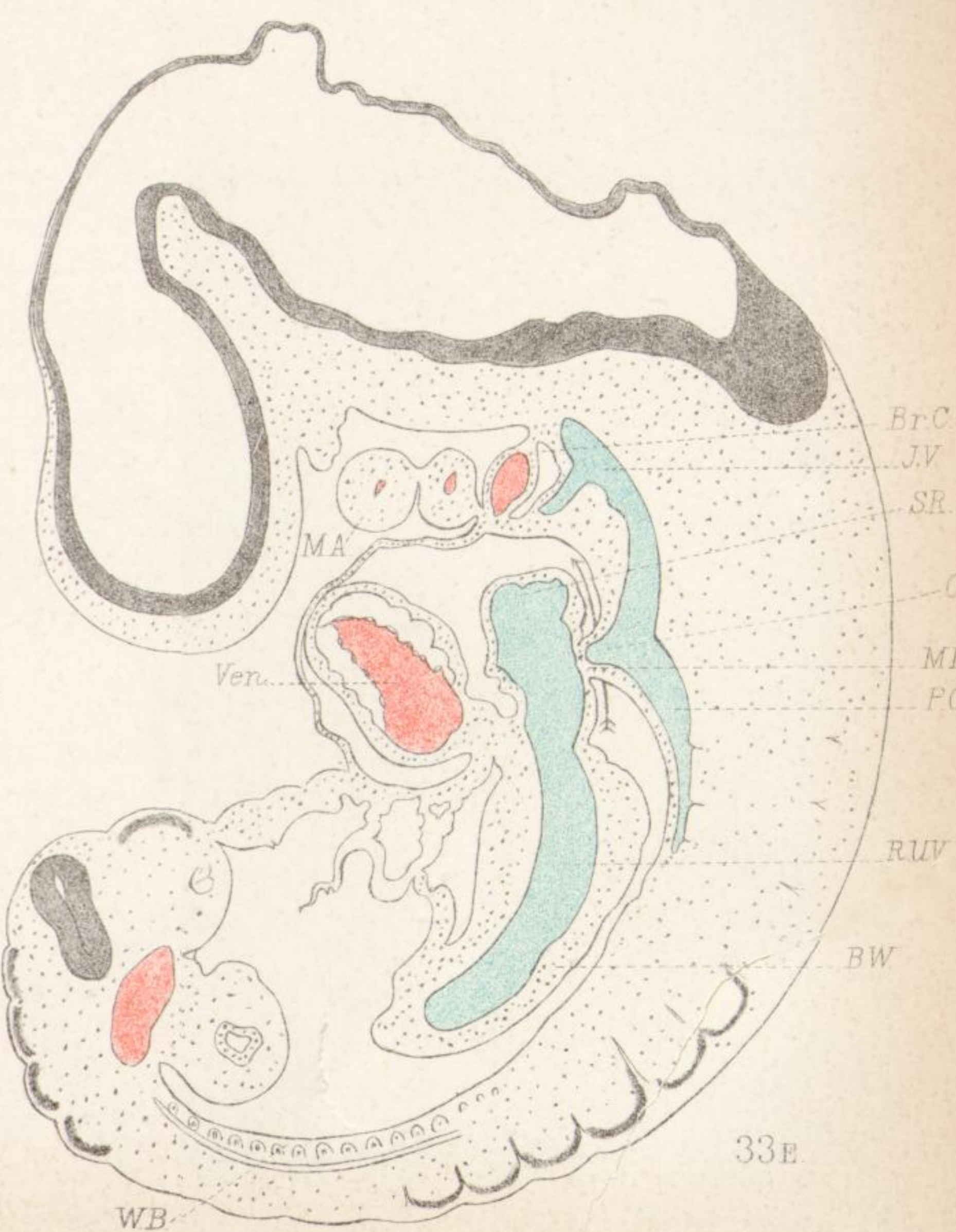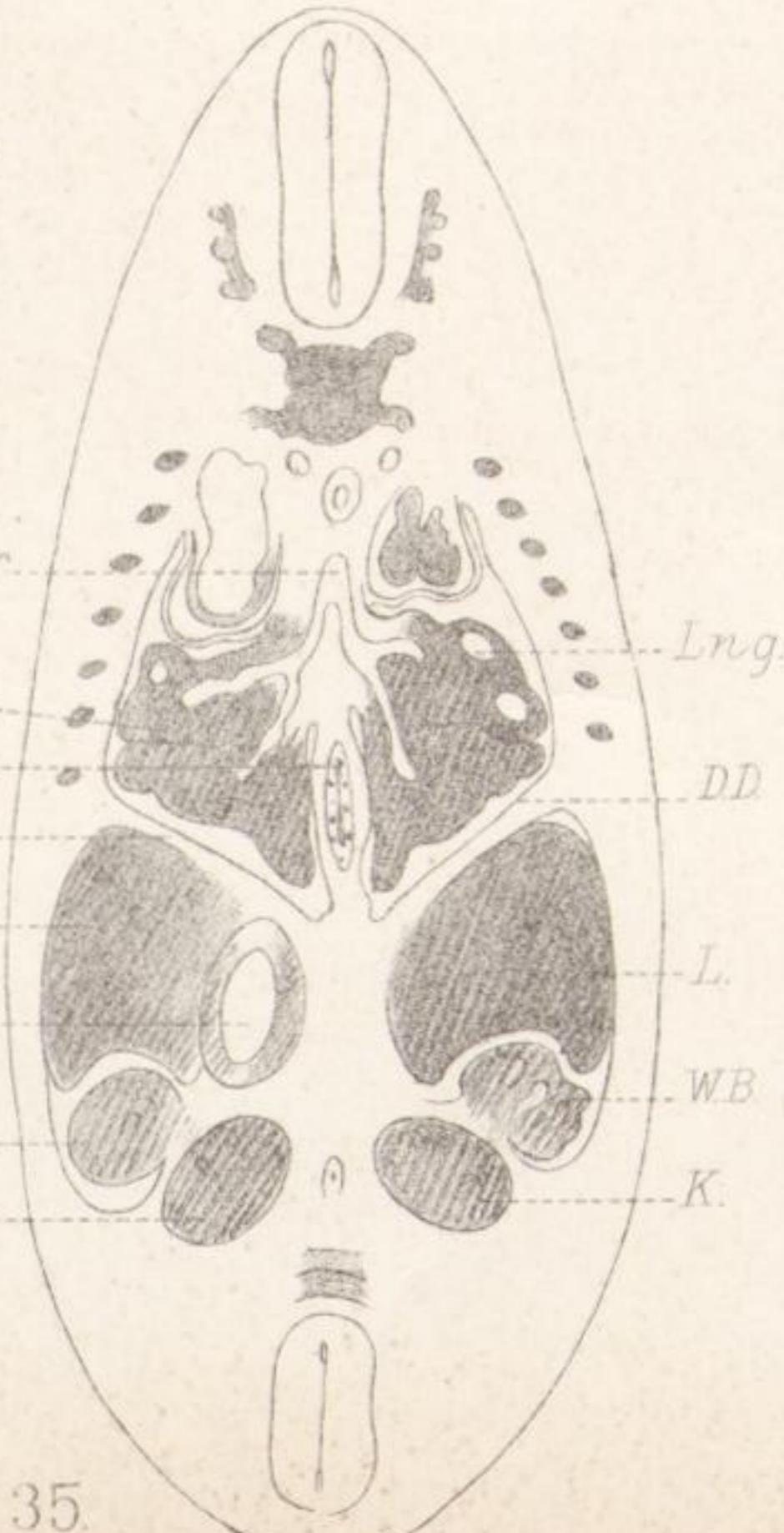
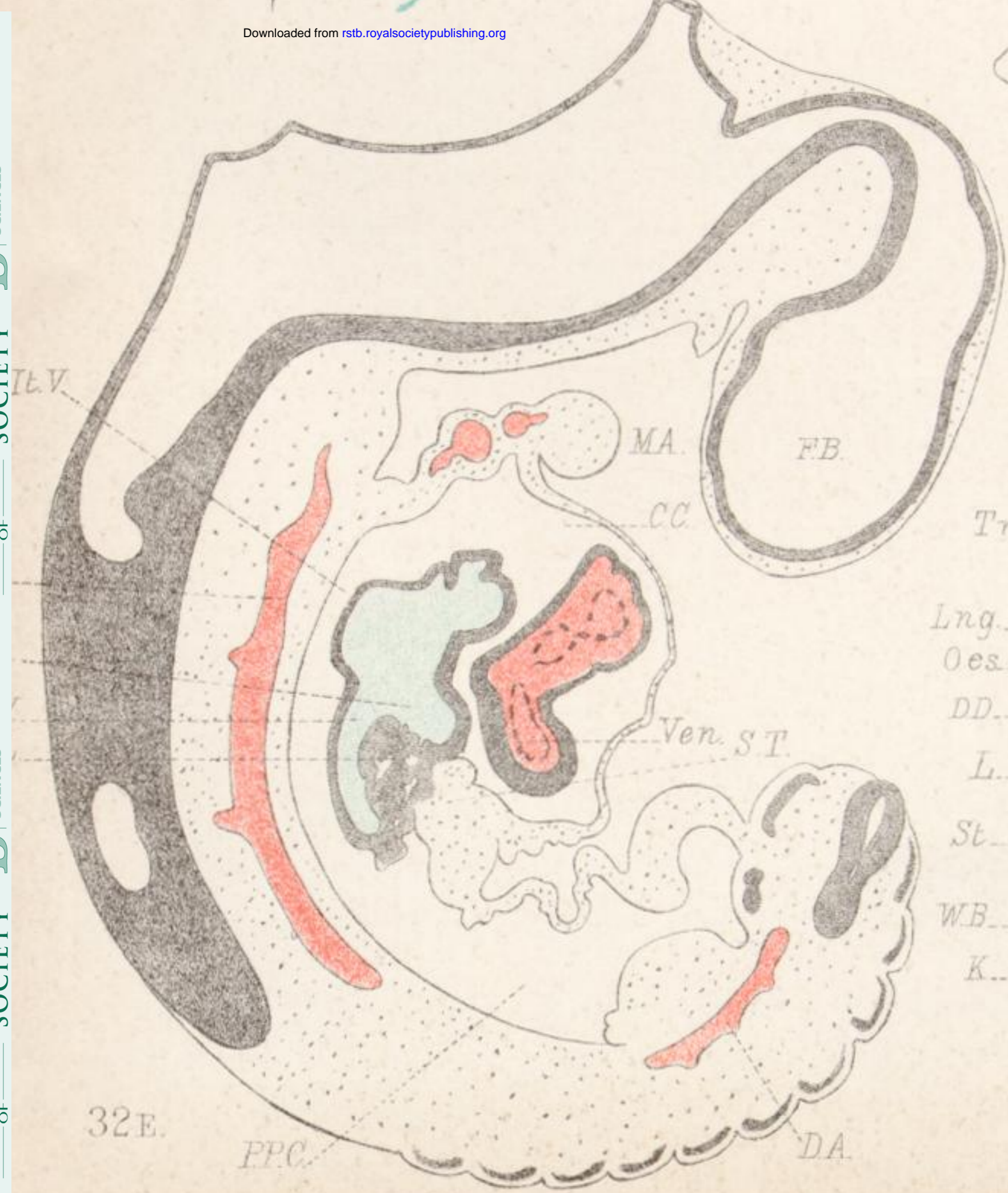
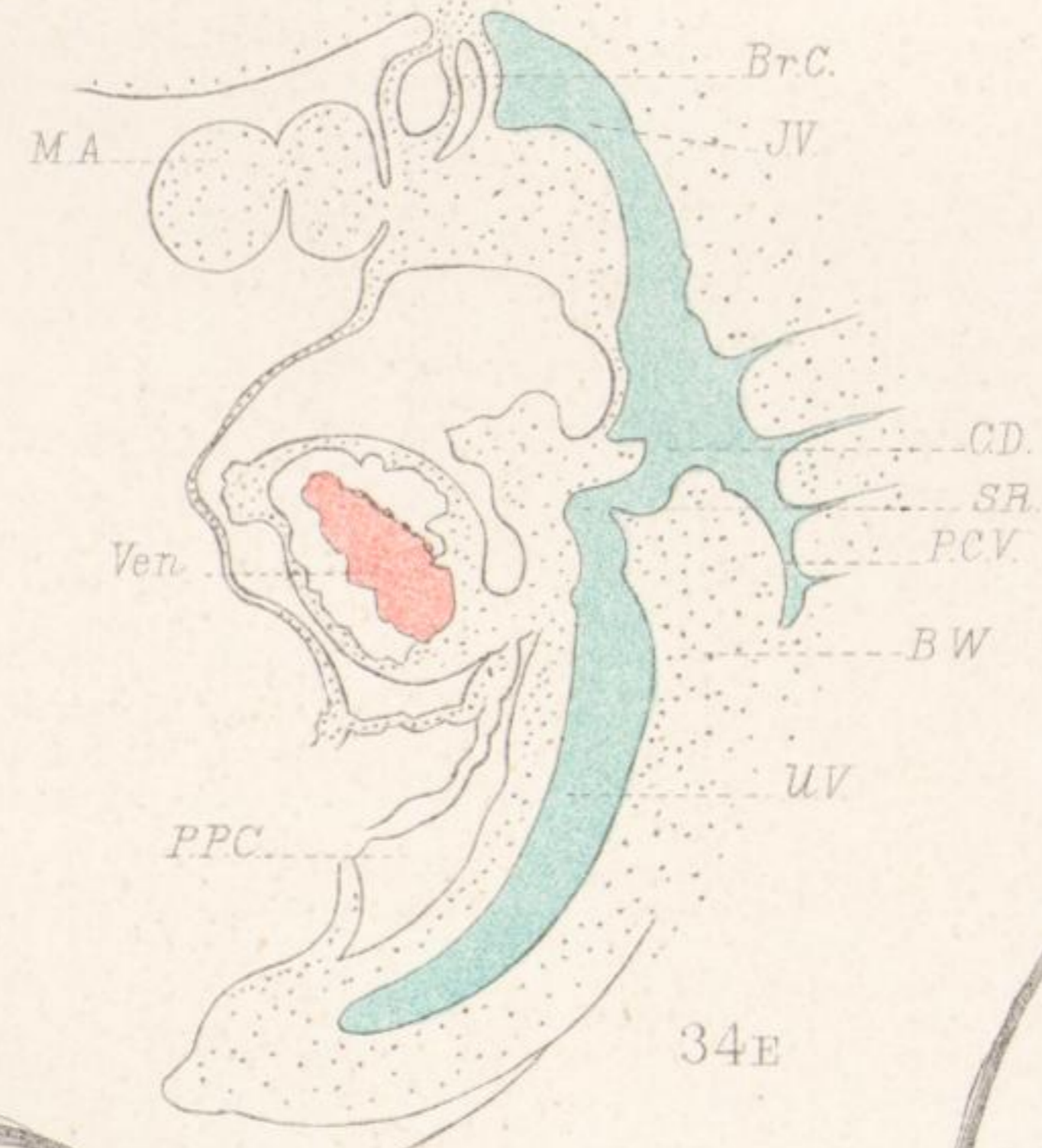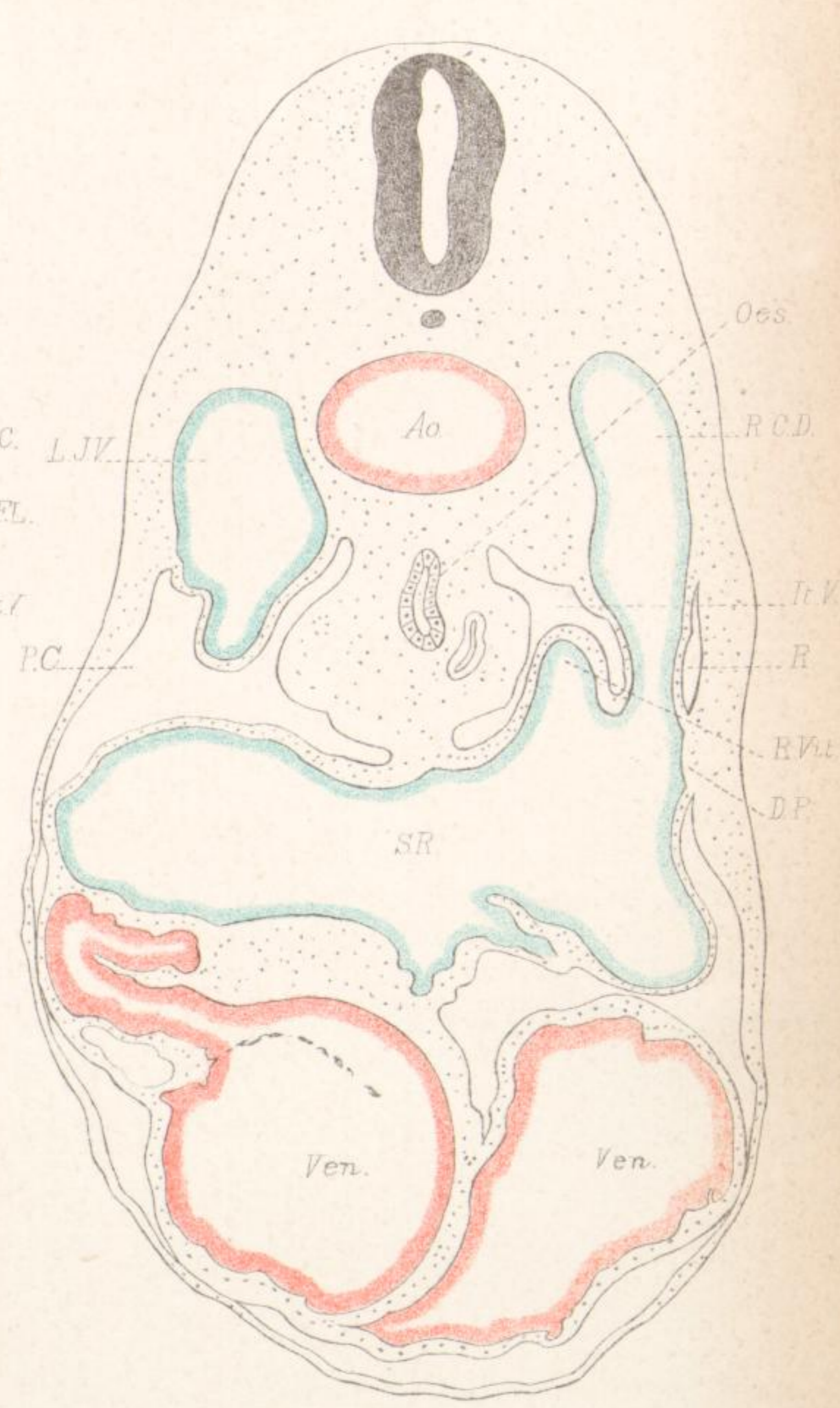
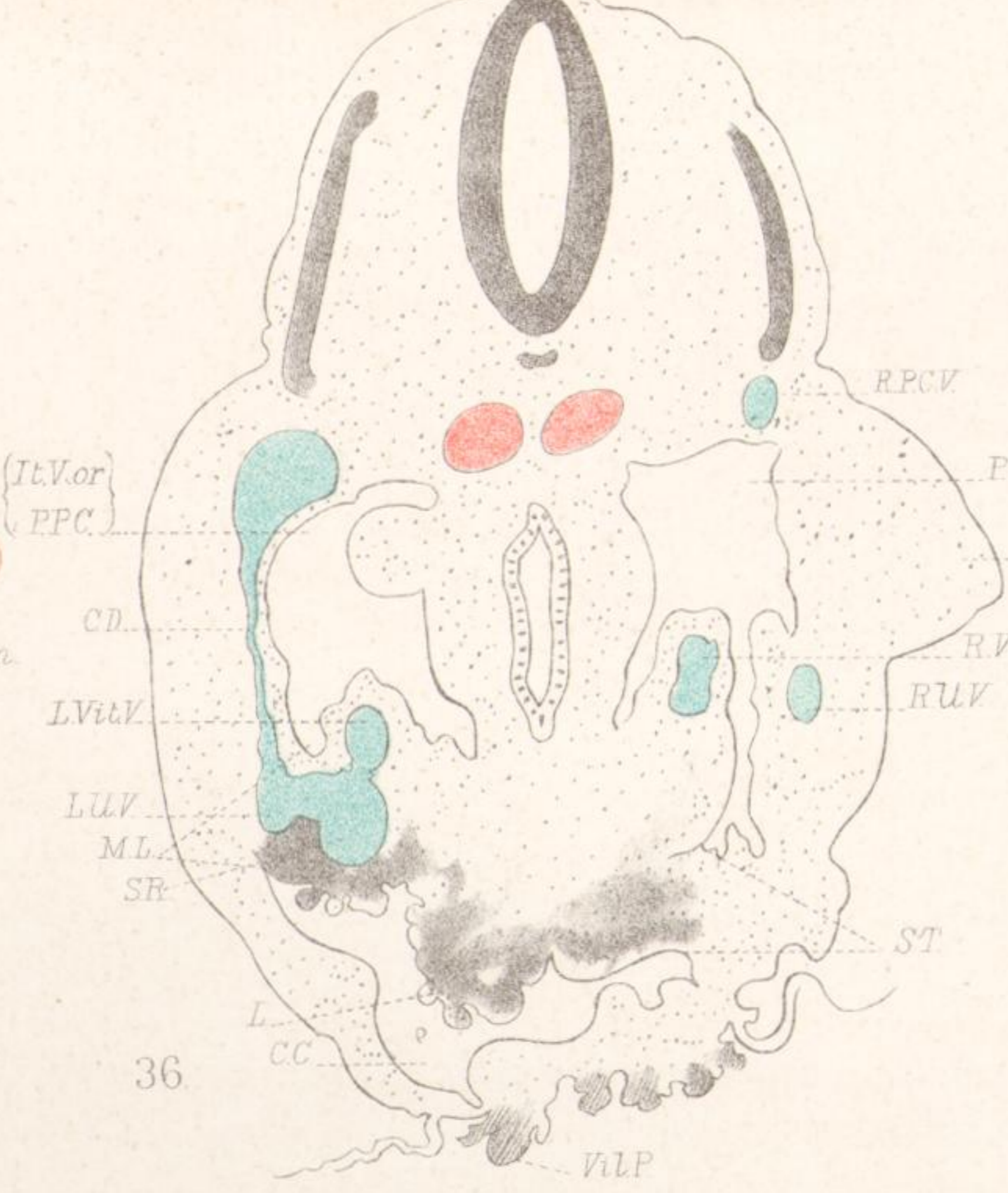
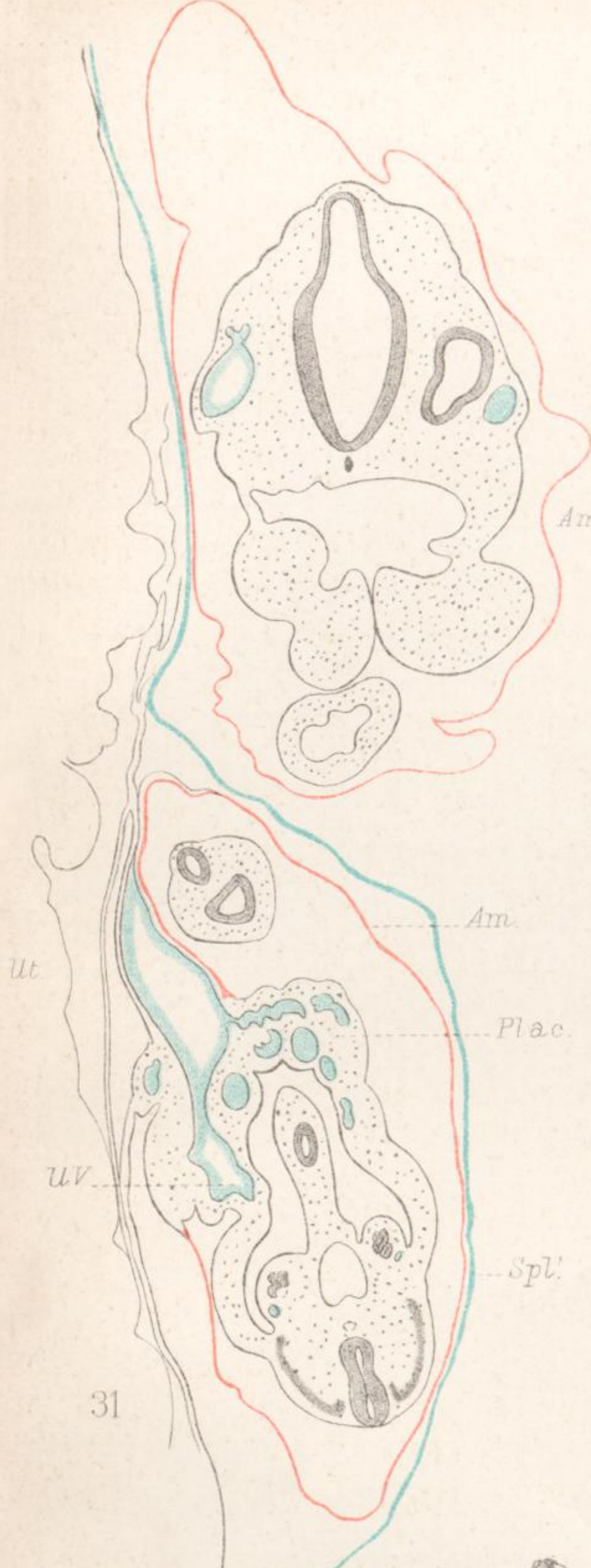
6.



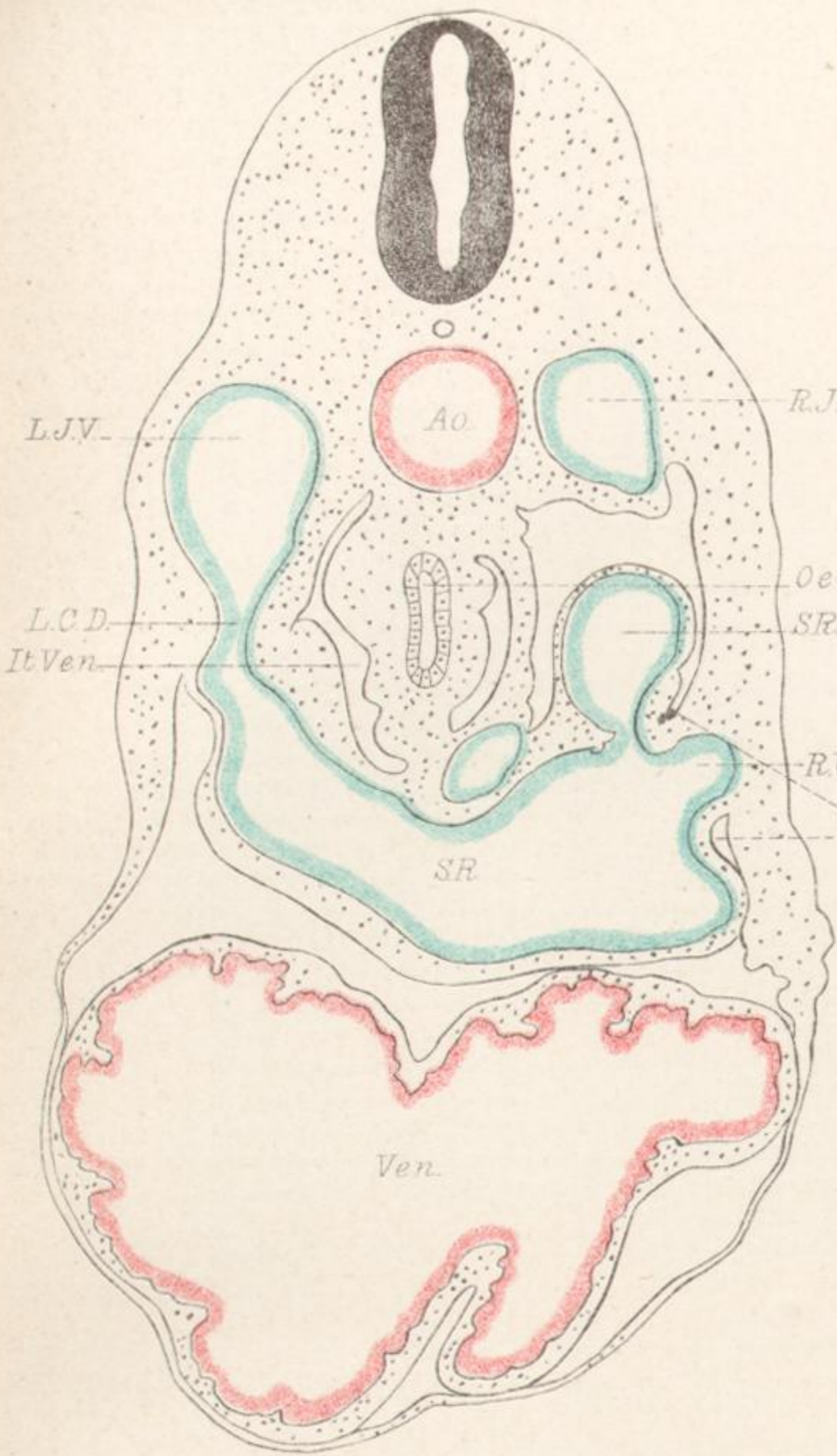


Downloaded from rnl.royalsocietypublishing.org

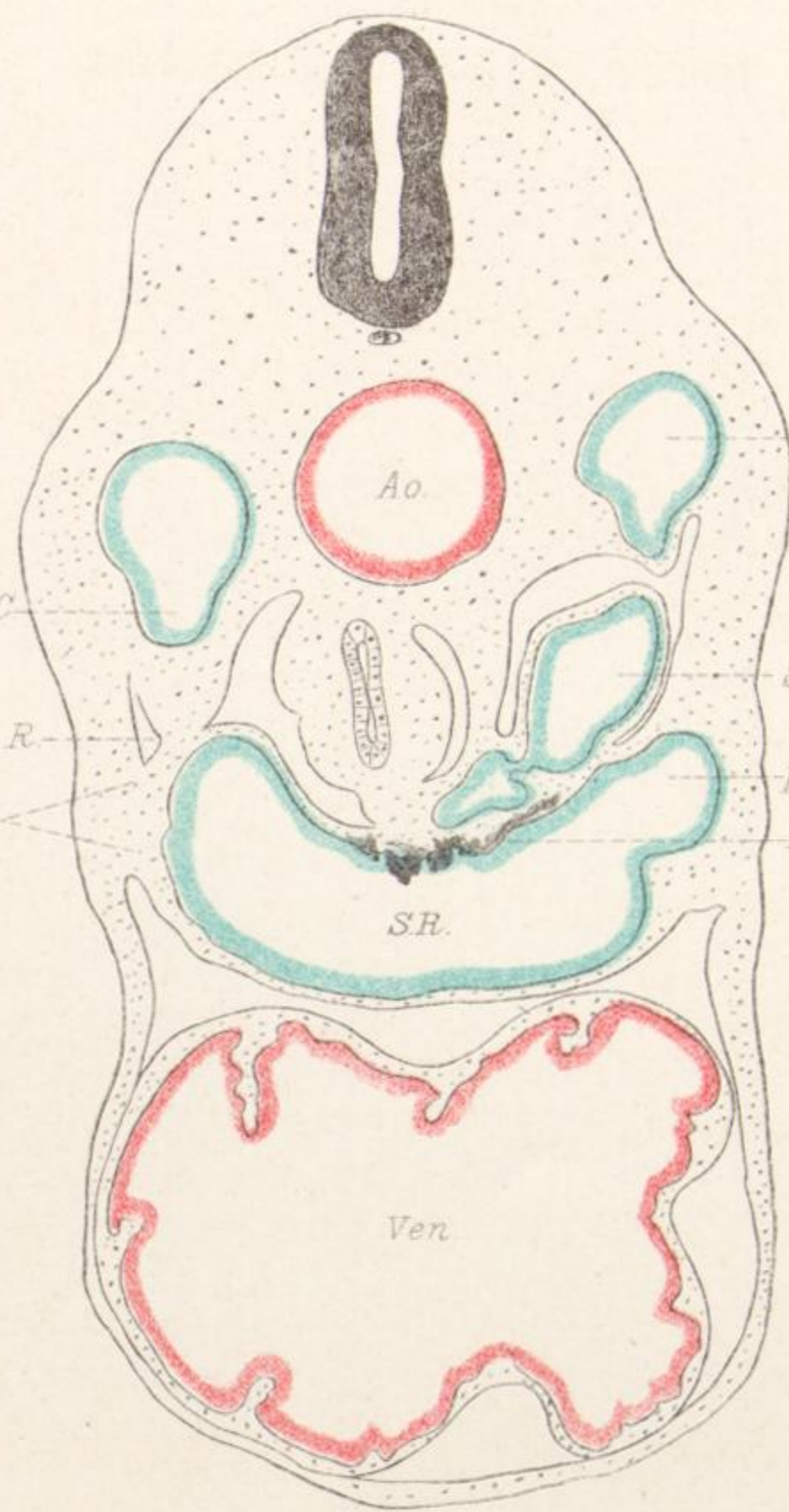




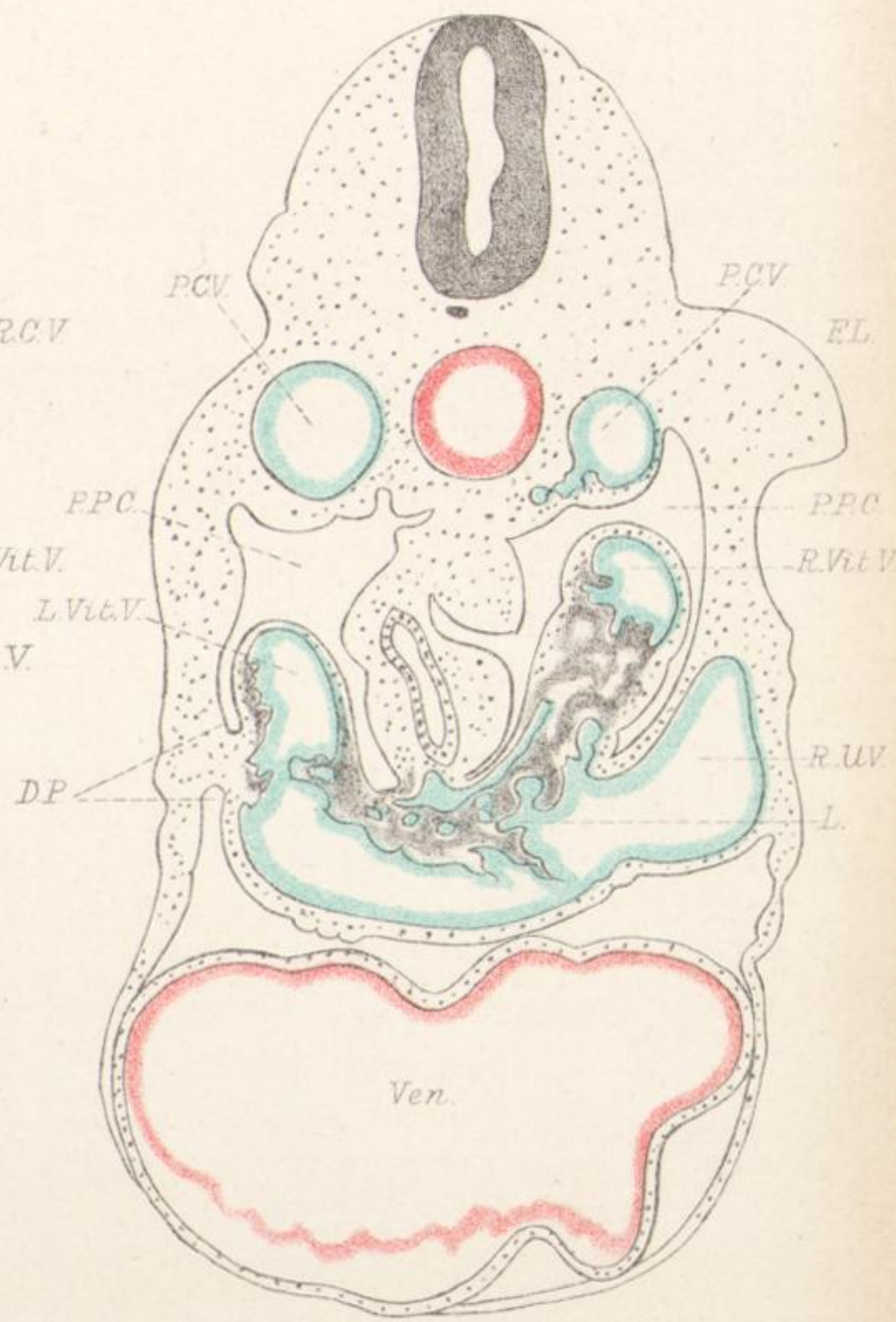
Downloaded from [rsb.royalsocietypublishing.org](http://rsb.royalsocietypublishing.org)



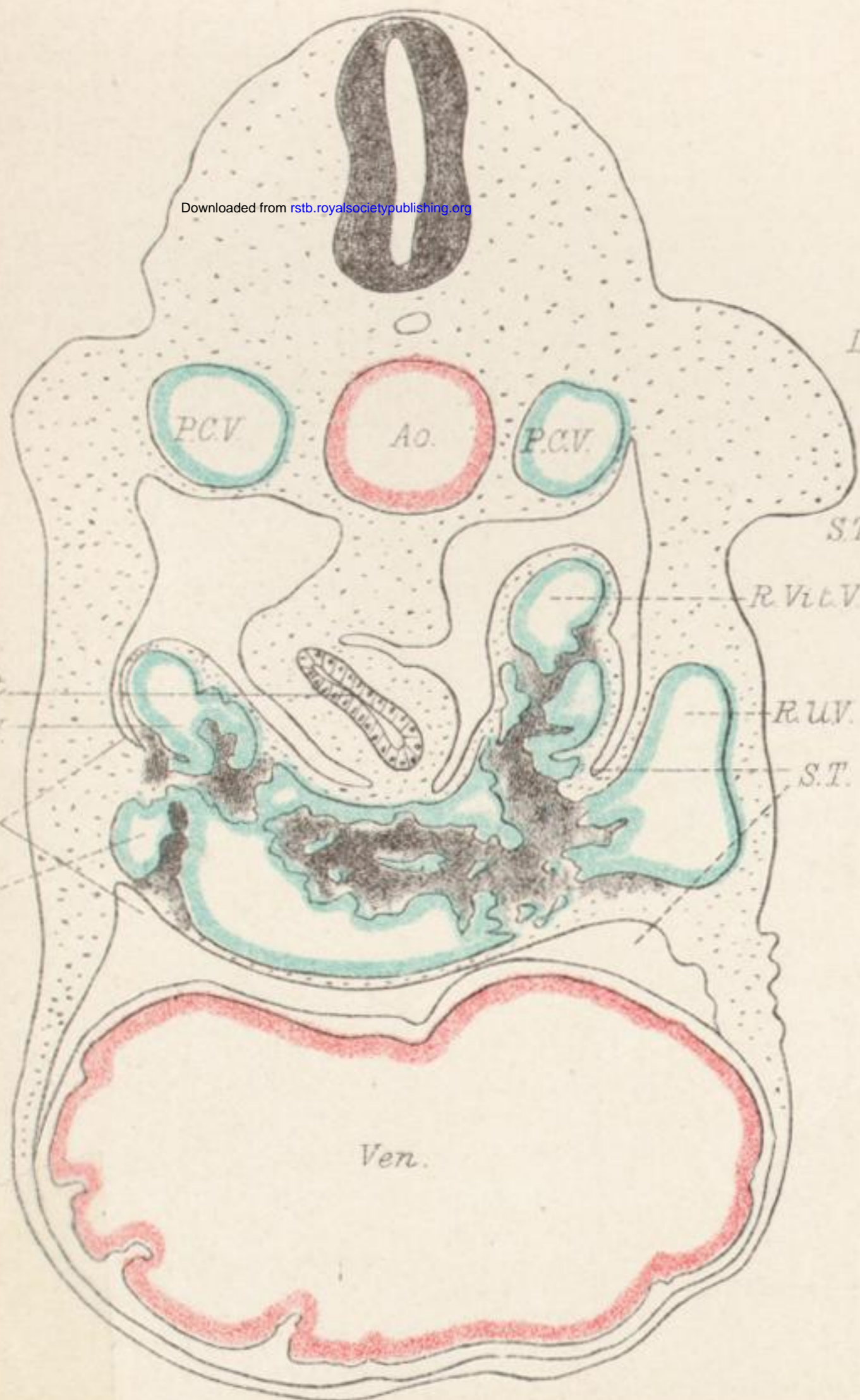
38F.



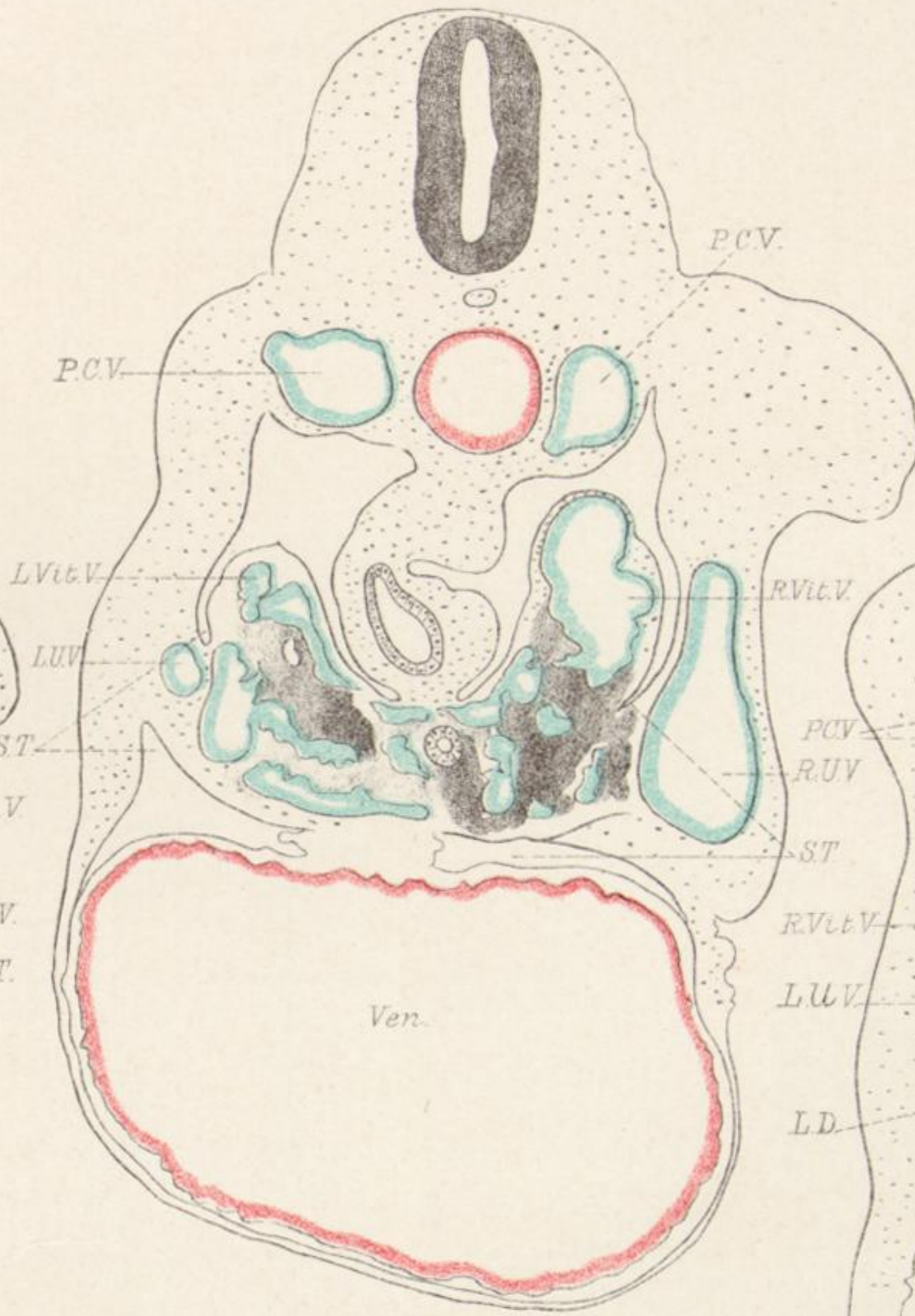
39F.



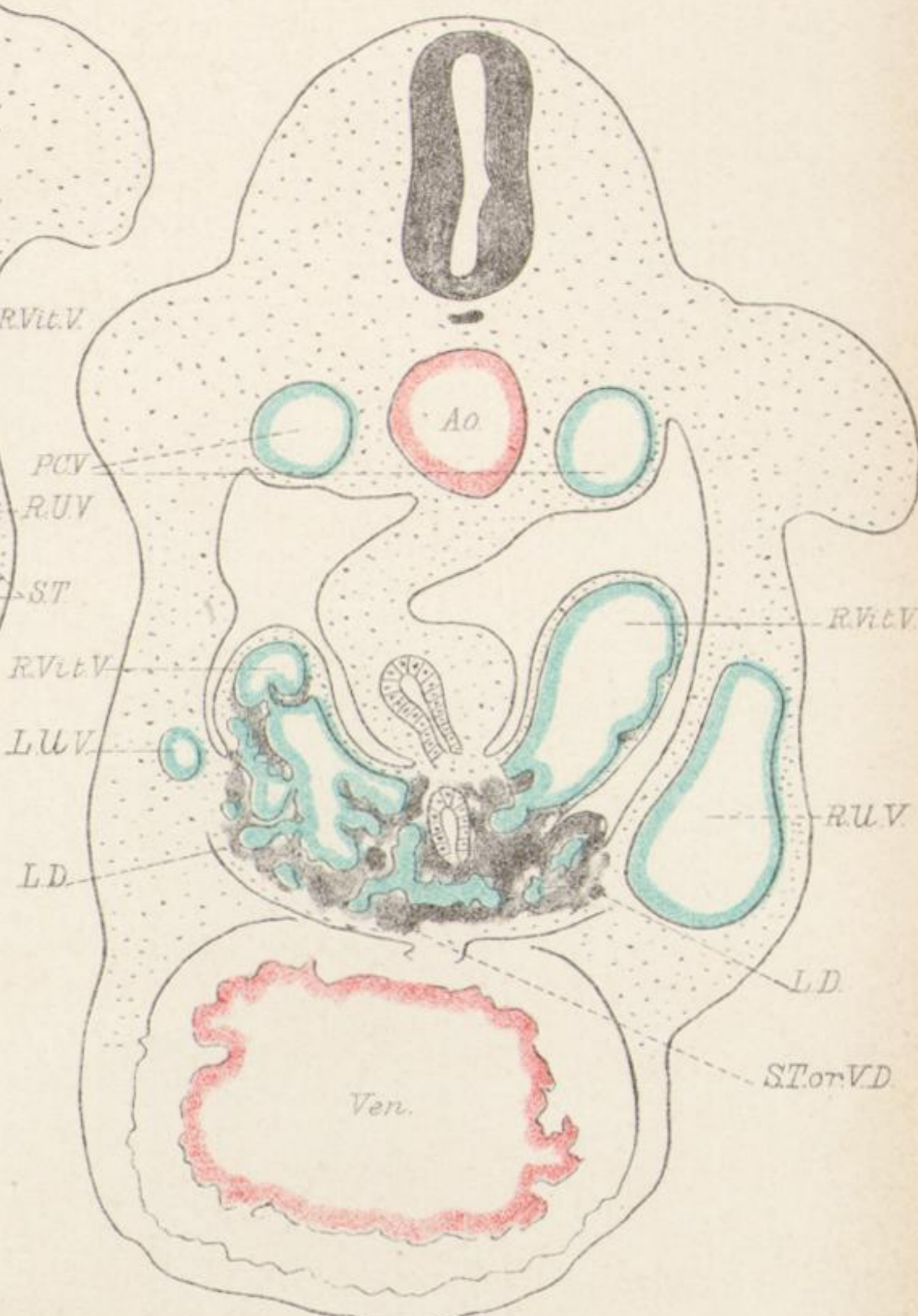
40F.



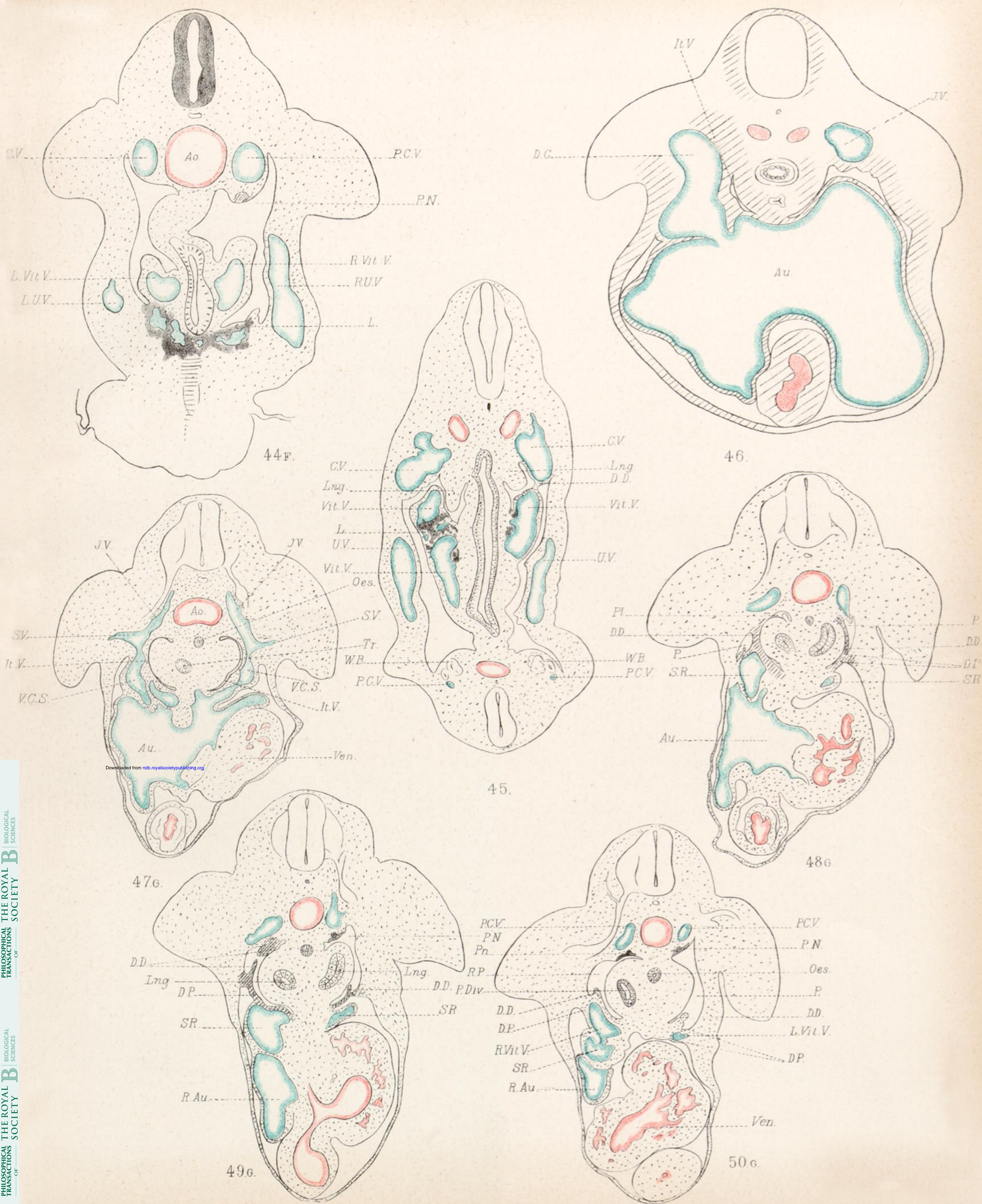
41F.

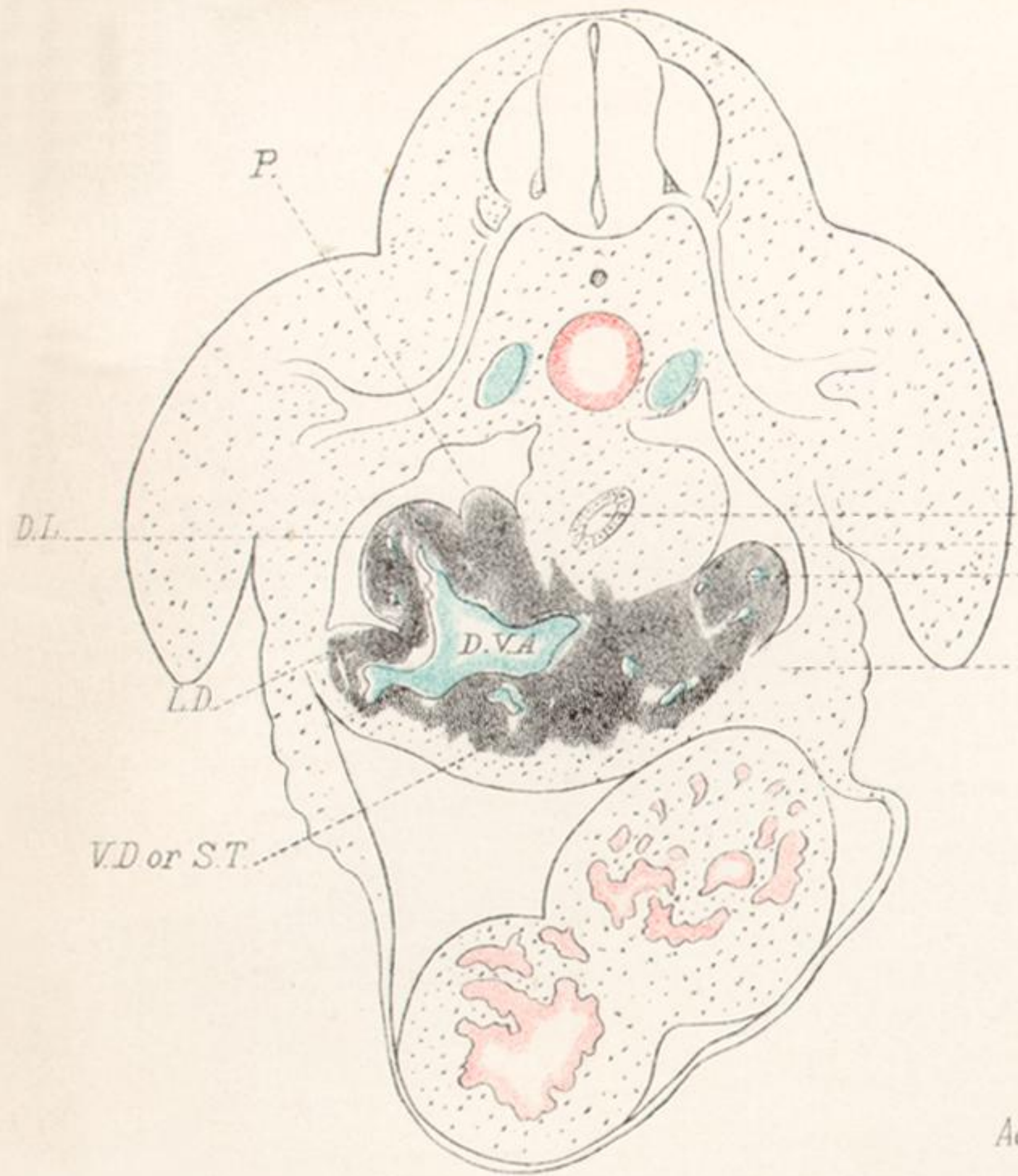


42F.

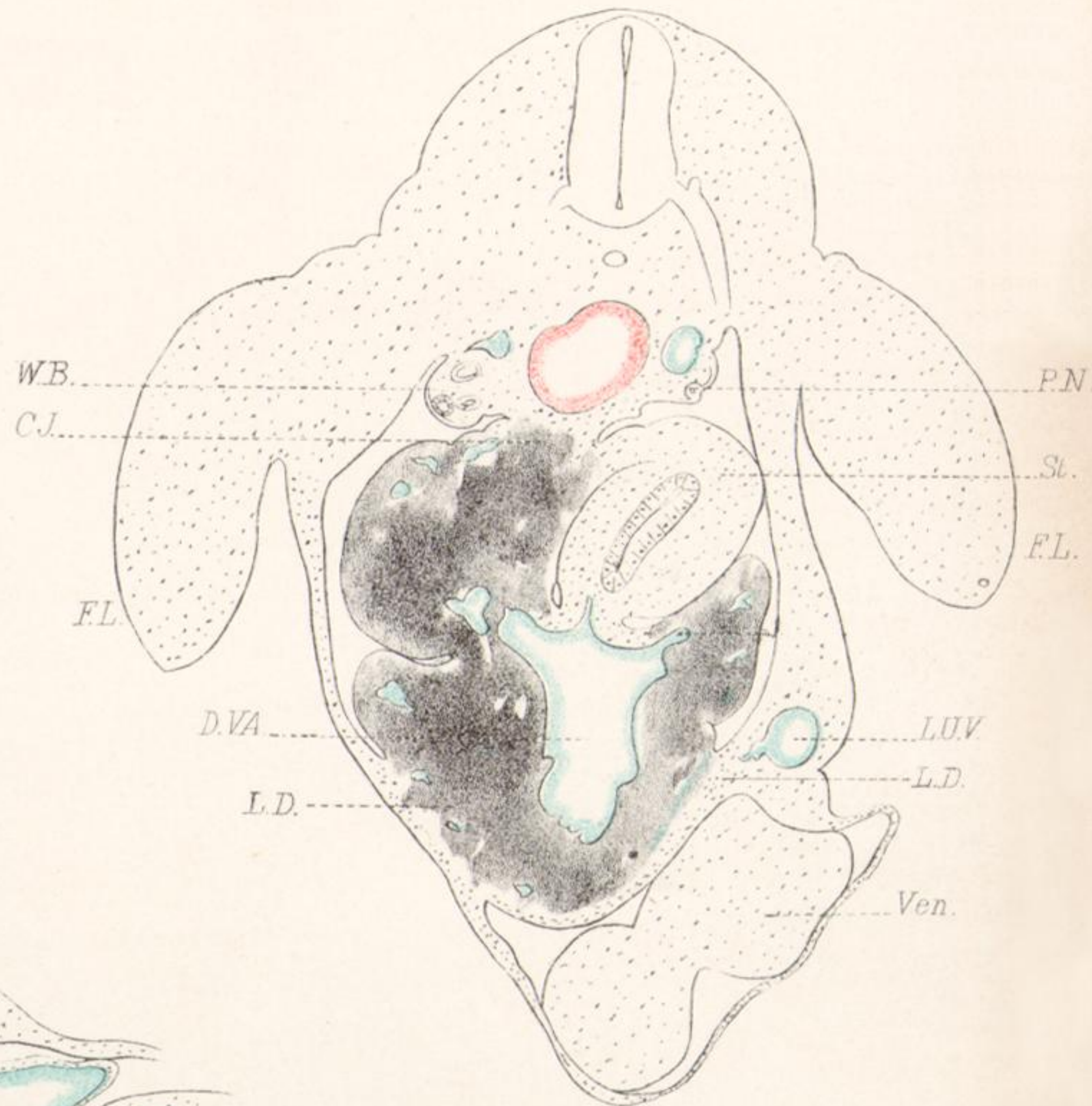


43F.

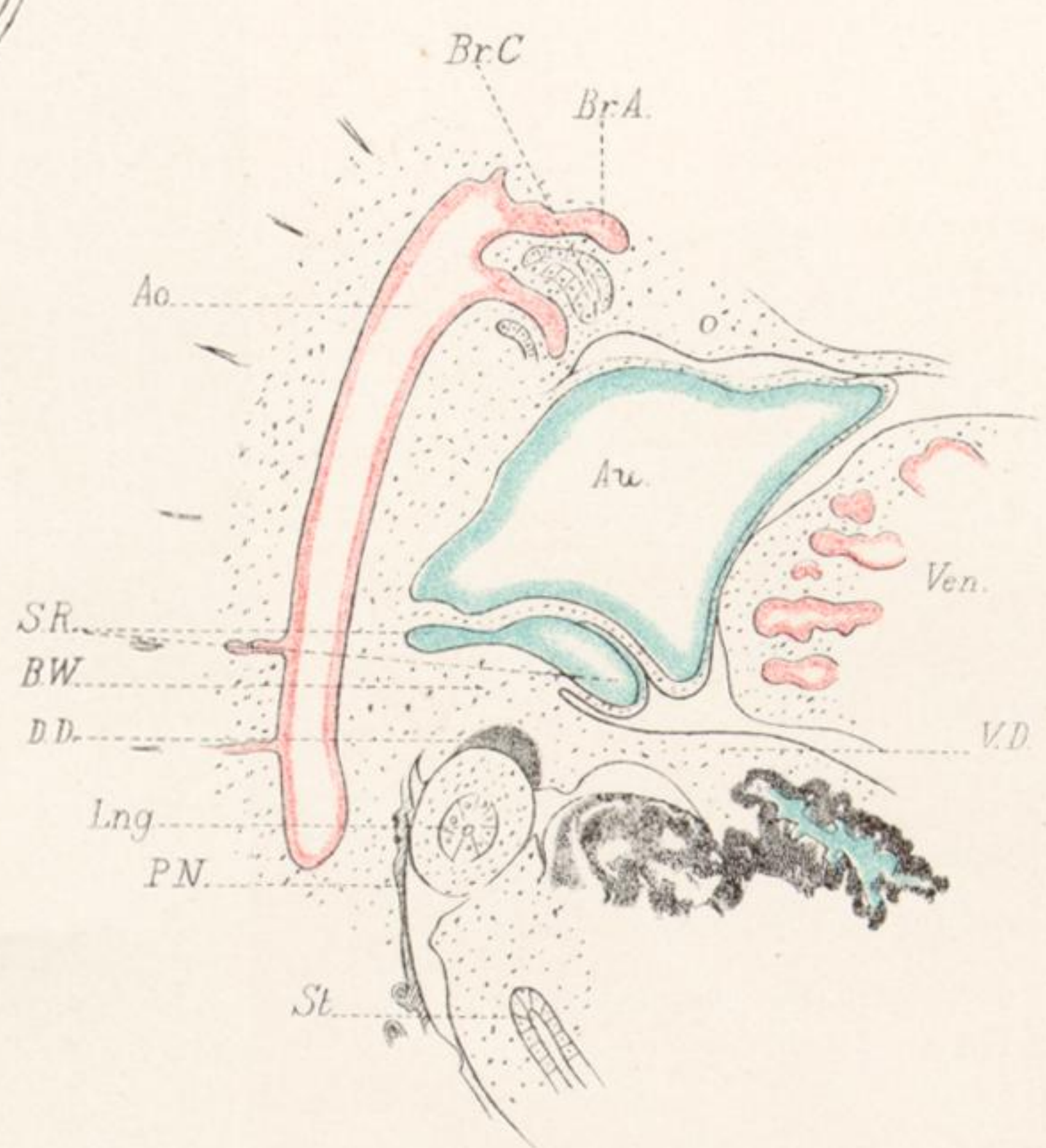




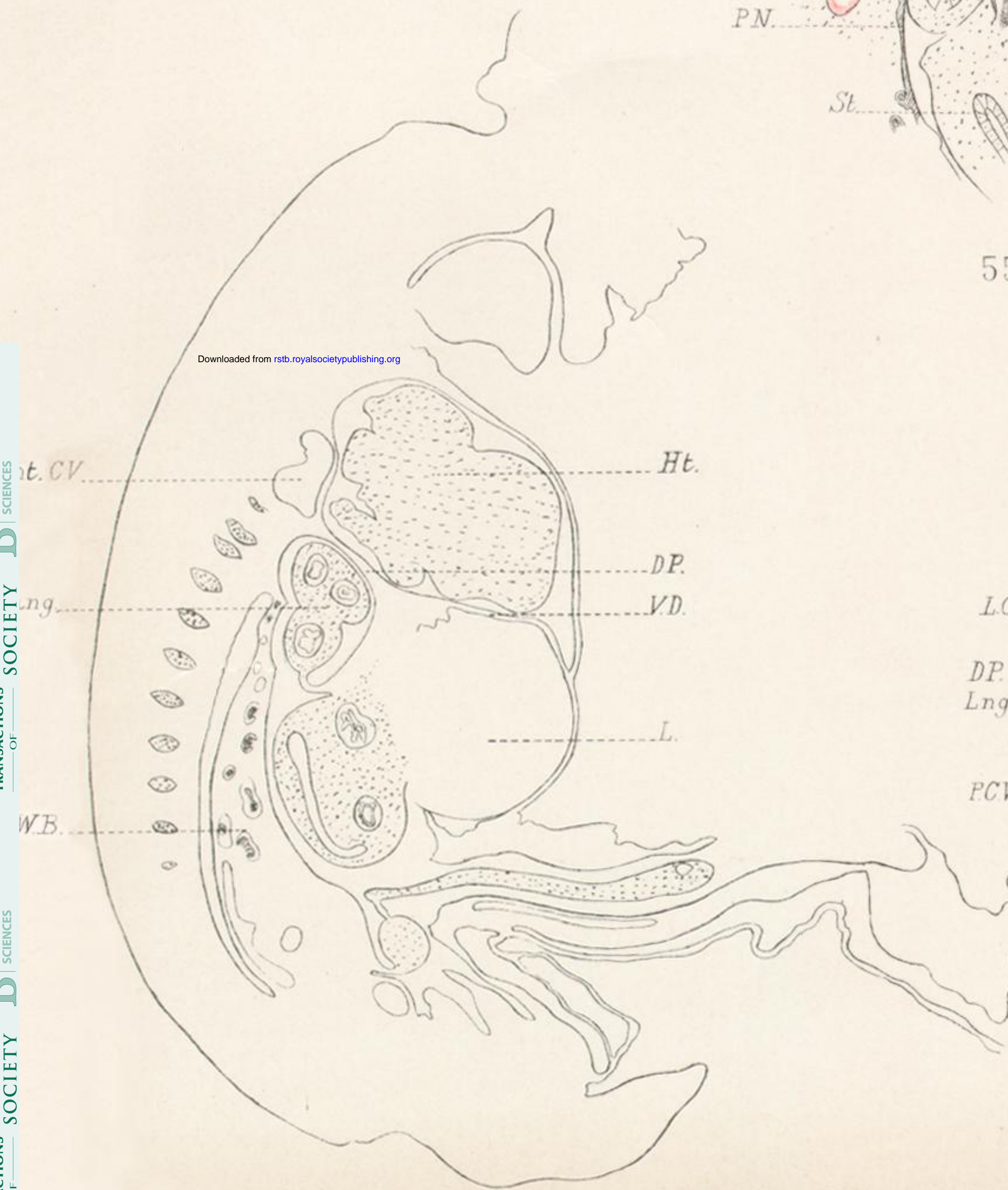
51 e.



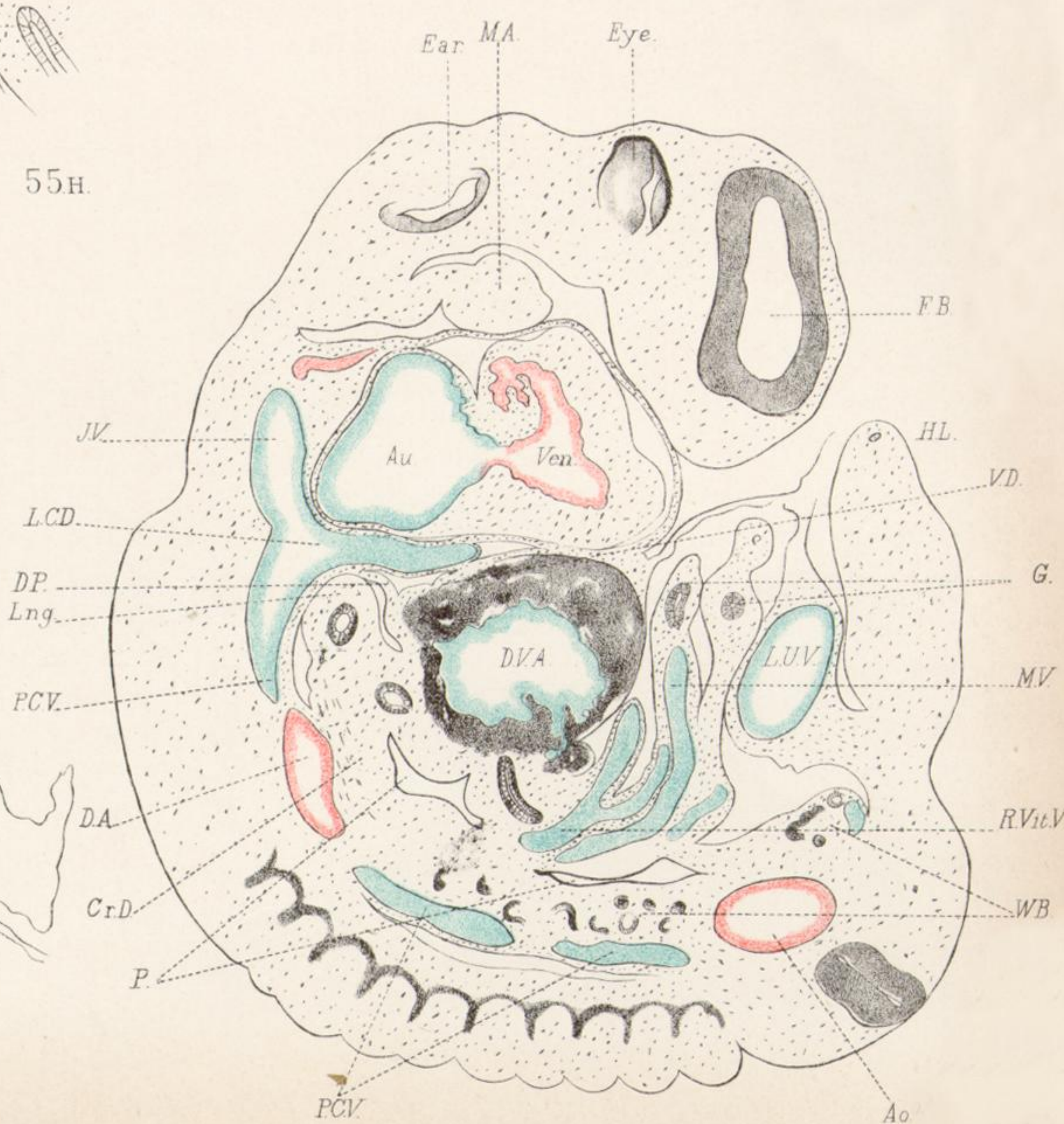
52 g.



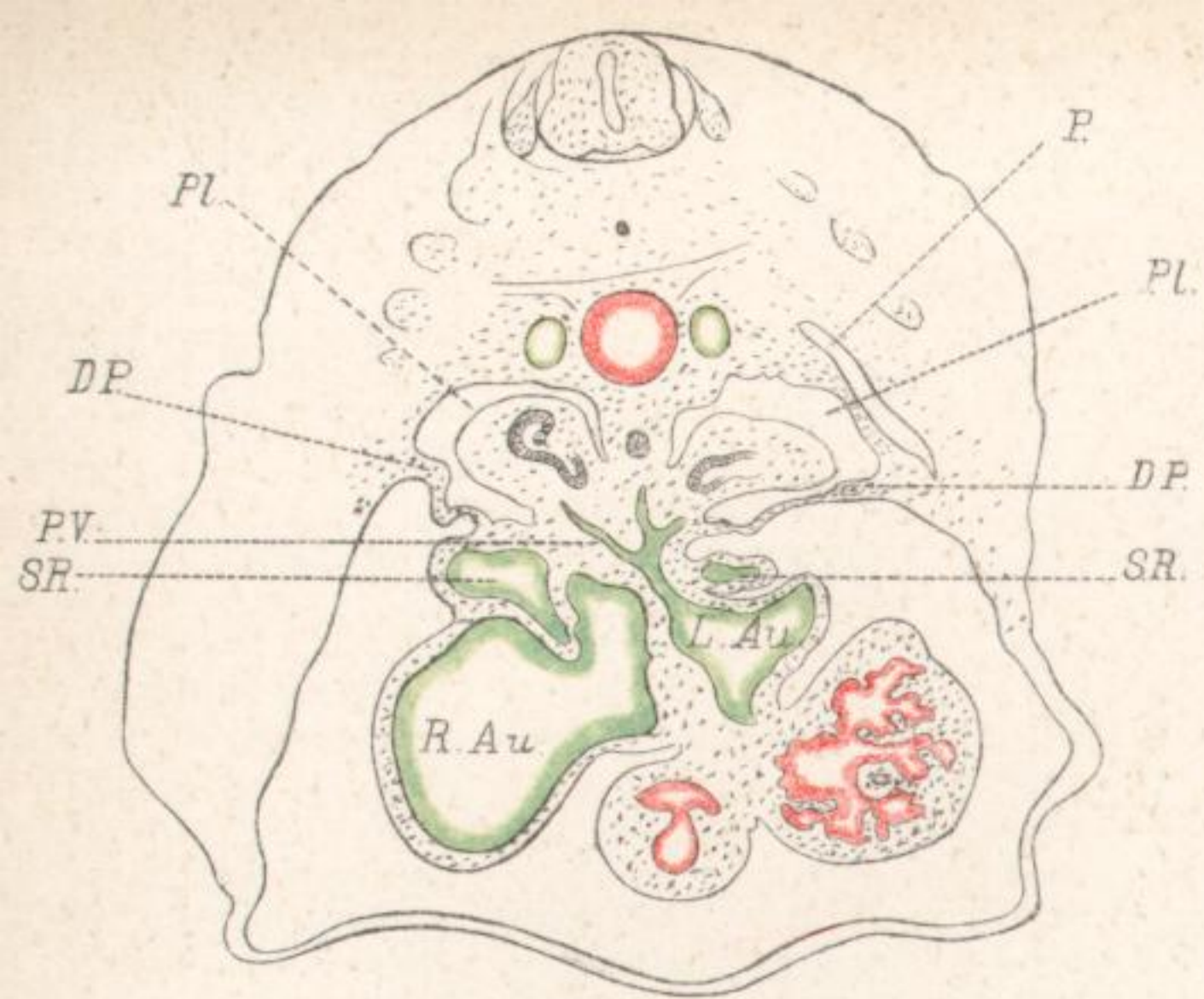
55 H.



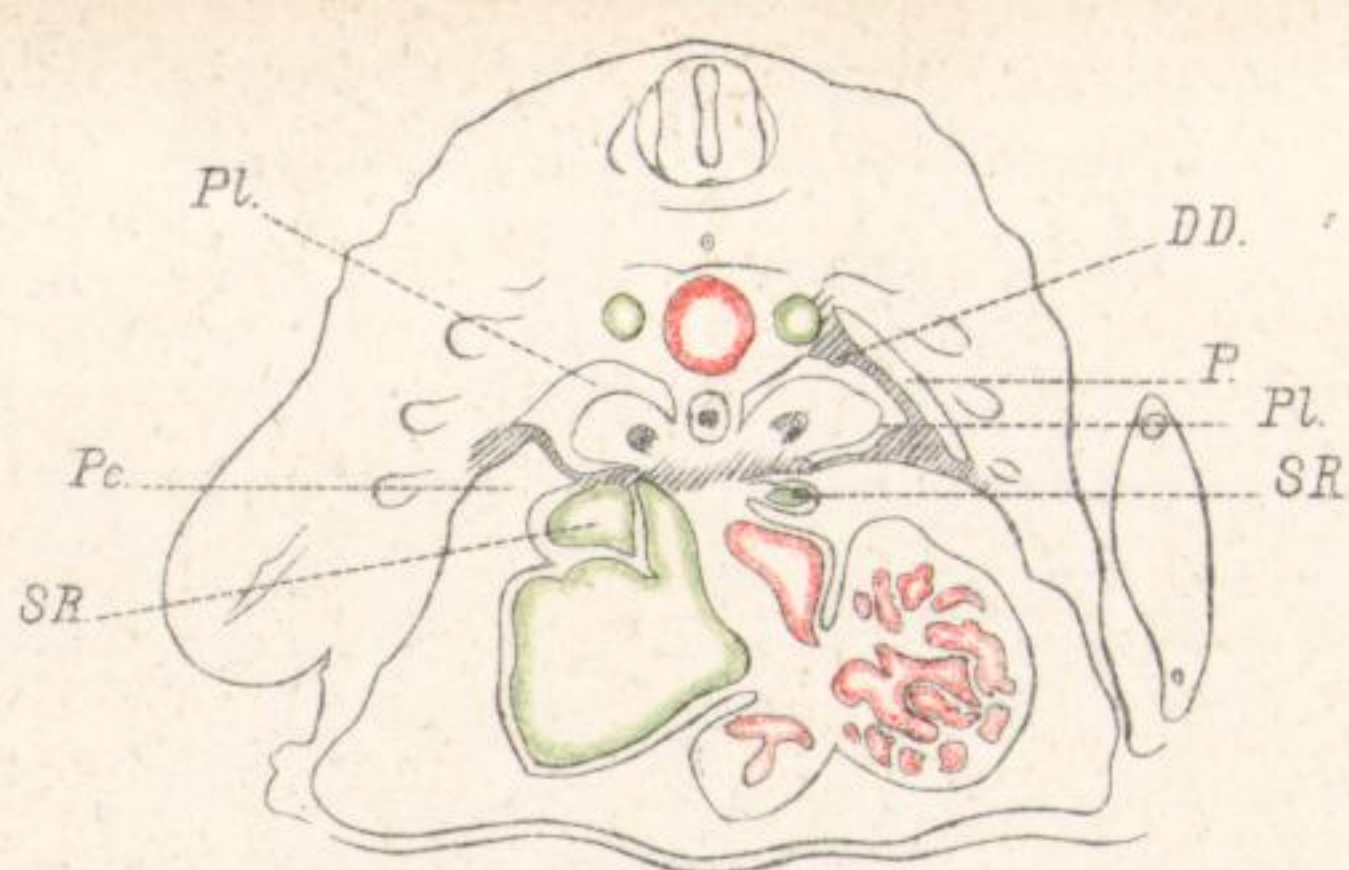
53.



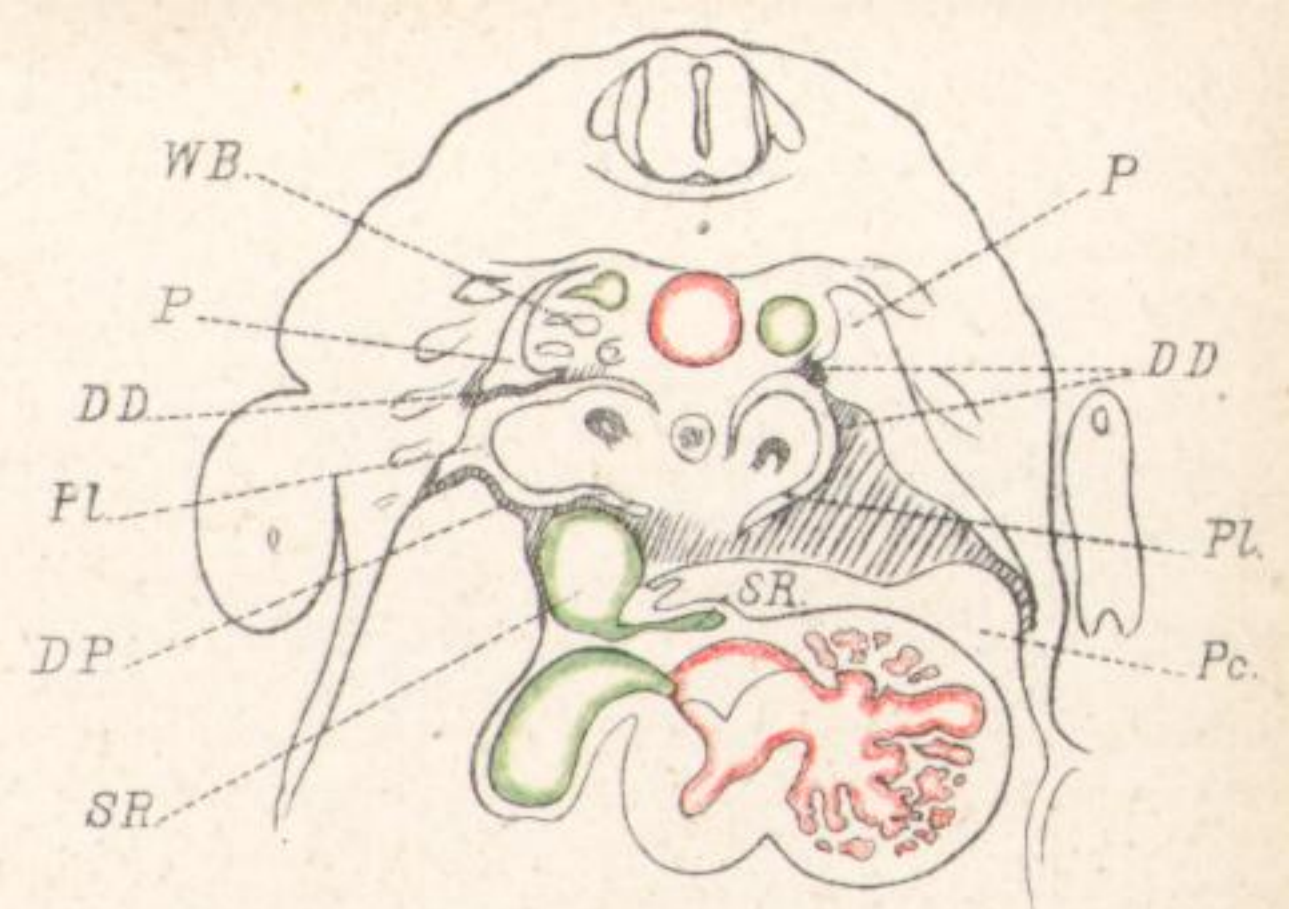
54 H.



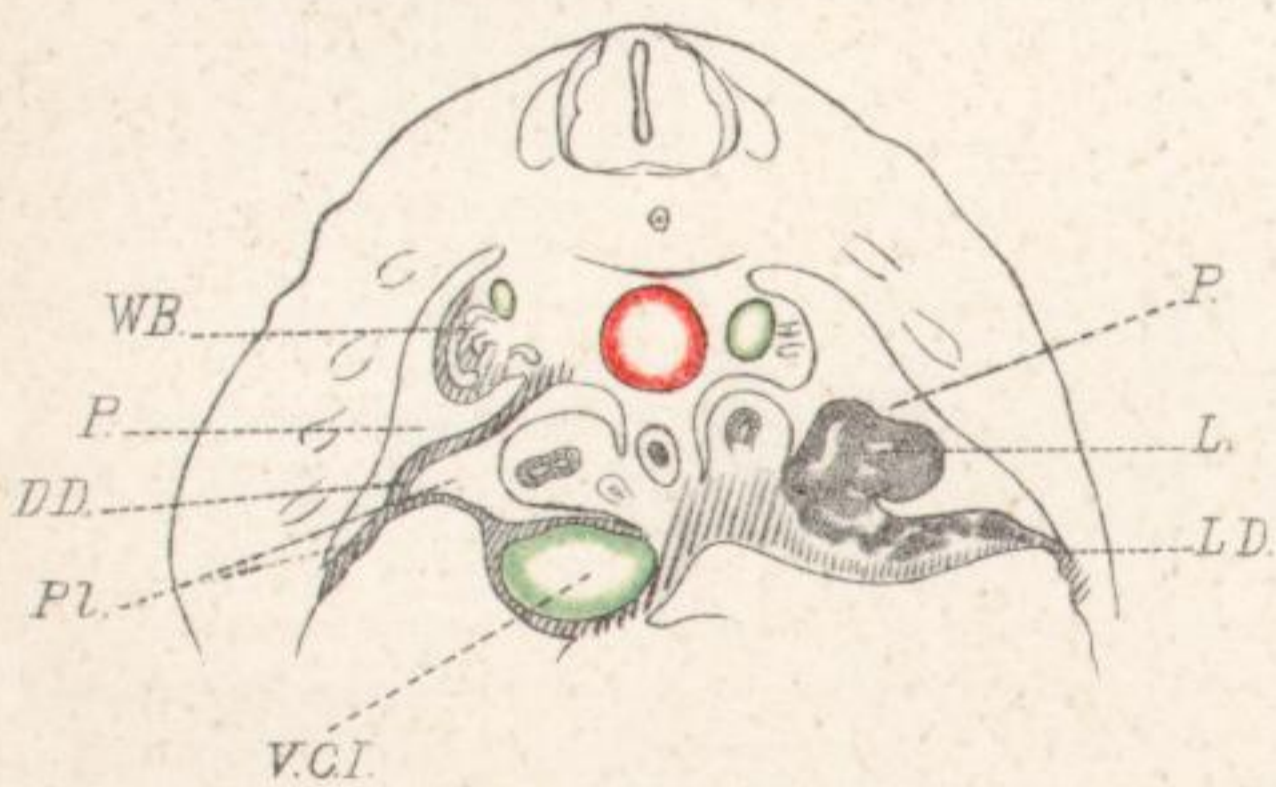
57.I.



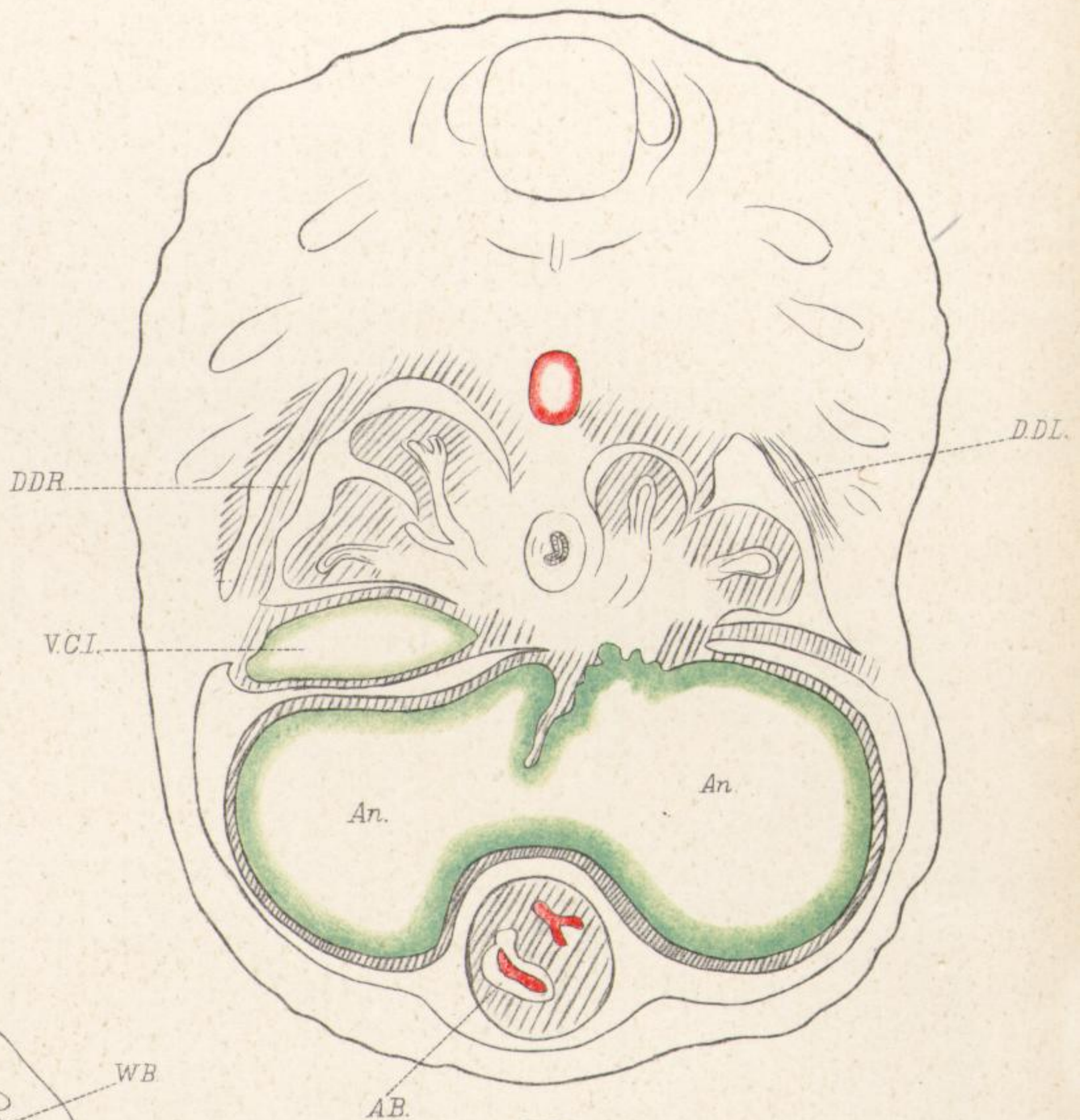
58.I.



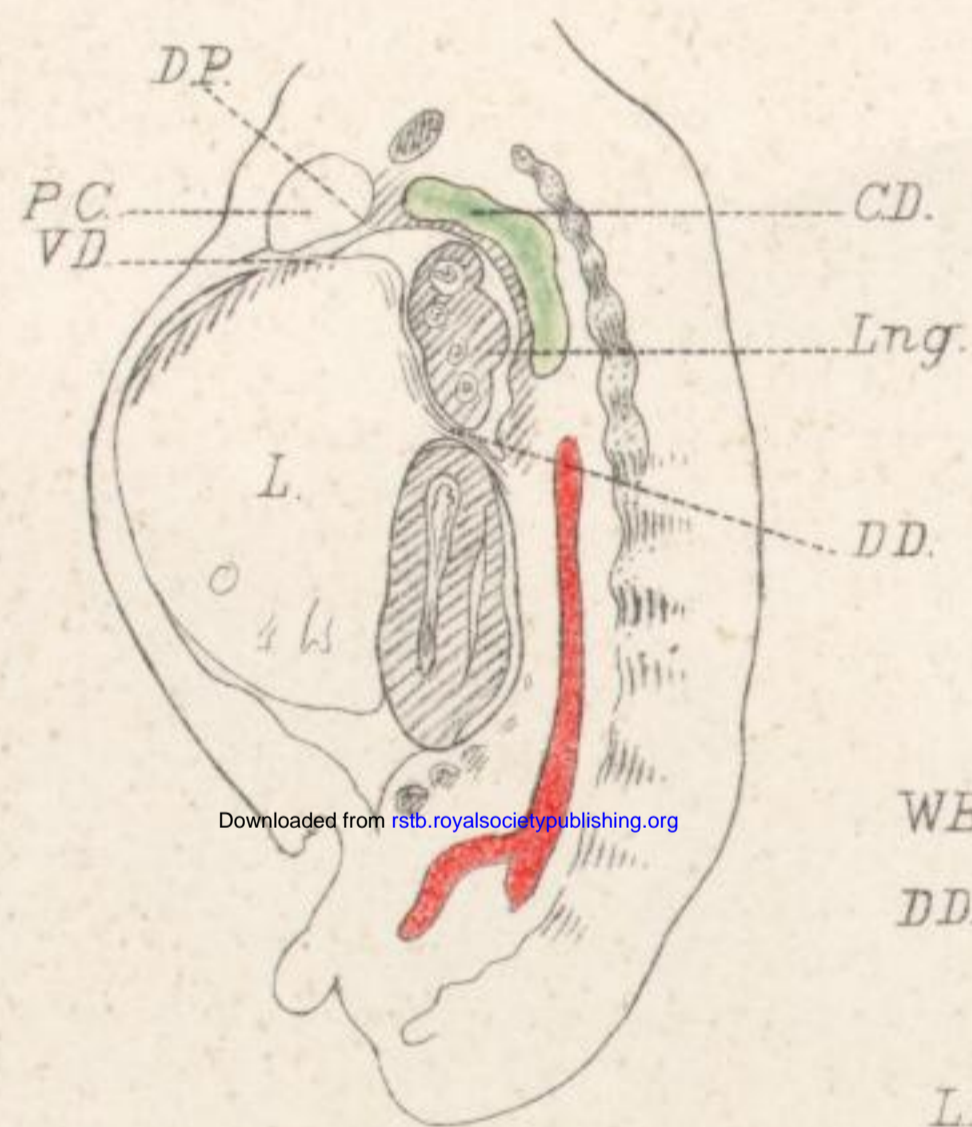
59.I.



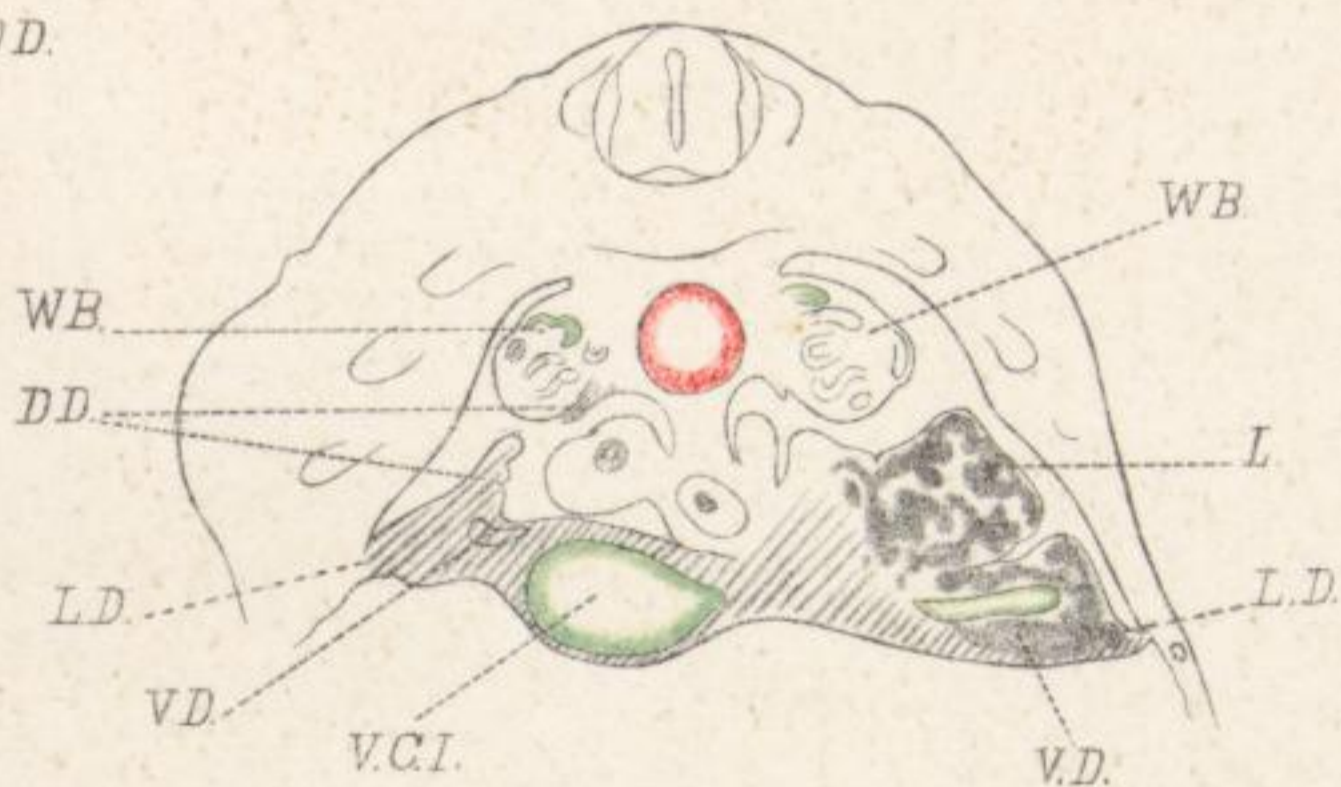
60.I.



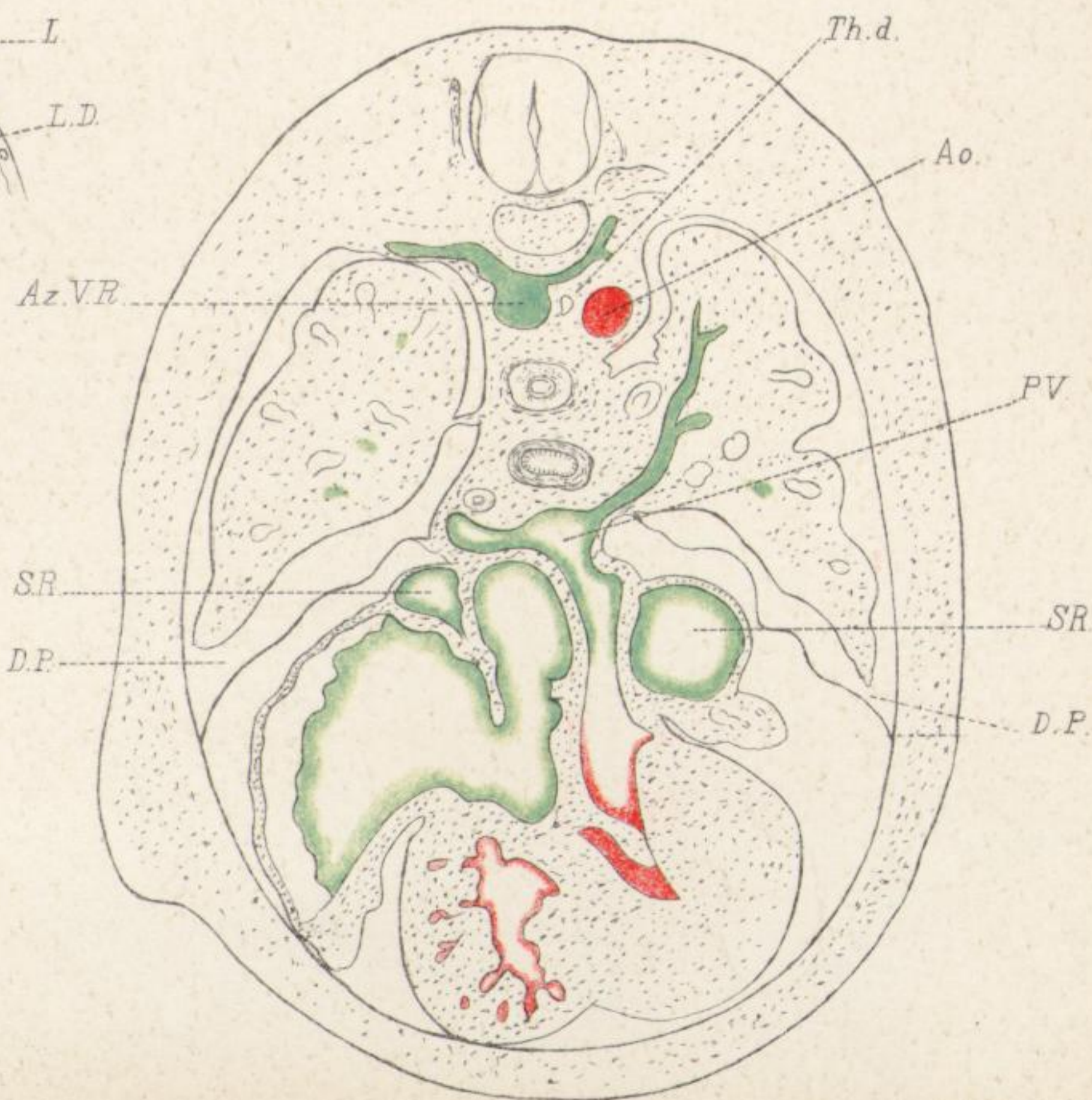
56.



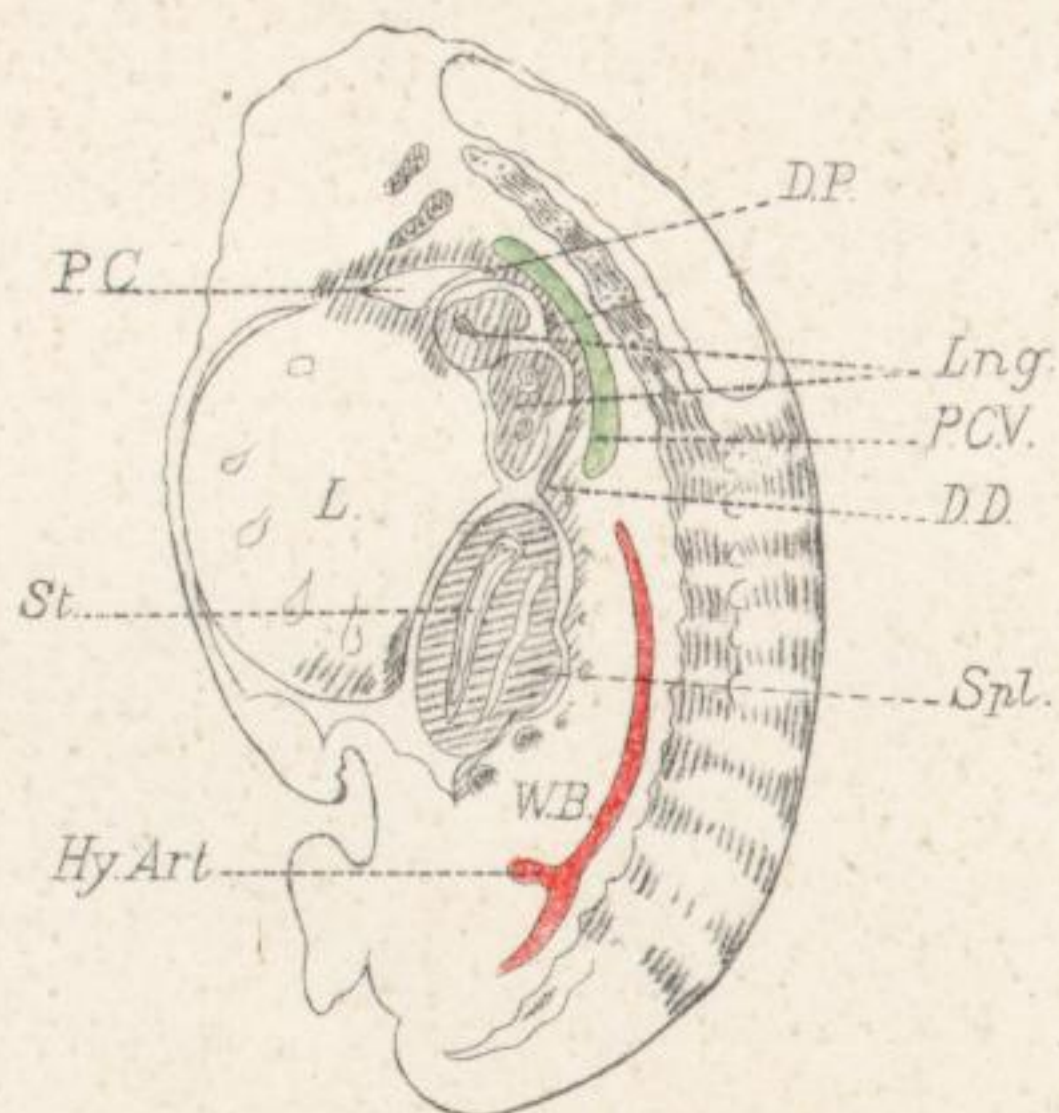
63.J.



61.I.



62.



64.J.